

PLEOMORPHIC ADENOMA OF THE PALATE

Purva Vijay Sinai Khandeparker¹, Anirudha Virginkar¹, Rakshit Vijay Sinai Khandeparker^{2*}, Omkar Shetye³

1. MDS, Oral and Maxillofacial Surgery, Private Practitioner, Margao, Goa

2. Lecturer, Department of Oral and Maxillofacial Surgery, Goa Dental College and Hospital, Goa

3. Assistant Professor, Department of Oral and Maxillofacial Surgery, Goa Dental College and Hospital, Goa

Submitted on: September 2017

Accepted on: September 2017

For Correspondence

Email ID:

rockdotcom1386@gmail.com

Abstract

Salivary gland neoplasms account for 2-3 % of all neoplasms occurring in the head and neck region. Pleomorphic adenoma is a mixed benign neoplasm mainly affecting the major salivary gland of which parotid is the most common. It may also affect the minor salivary glands and present as an intraoral mass over the palate or lip. We hereby report a case of pleomorphic adenoma of the hard palate. An effort has also been put into reviewing the existing literature on this entity.

Keywords: Pleomorphic adenoma, benign, neoplasm, palate, intraoral.

Introduction

Salivary gland neoplasms account for 2-3 % of all neoplasms occurring in the head and neck region. Pleomorphic adenoma is the most common neoplasm affecting the major and minor salivary glands. It derives its name from the architectural pleomorphism.¹ It accounts for 53 to 77 % of parotid tumors, 44 to 68 % of submandibular tumors and 33 to 43 % of minor salivary gland tumors.² Palate (42.8-68.8%) is the most commonly affected intraoral site followed by lip (10%), buccal mucosa/cheek (5.5%), throat (2.5%), retromolar area (0.7%), floor of the mouth and alveolar mucosa.^{3,4}

Pleomorphic adenoma develops as a painless, slow growing, firm mass which is generally mobile except when it occurs in the hard palate. It can develop at any stage of life but the highest incidence is between 30-60 years with slight female predilection.^{1,4,5} Treatment for the pleomorphic adenoma is radical excision of the tumor.

Case Report

A 17-year female reported with a chief complaint of a slow growing, painless mass in the upper left palatal region for the past 1 year. The patient had no relevant medical history.

Intraoral examination revealed a single ovoid mass measuring 1.8 x 2 cm in diameter in relation the hard palate approximately extending 9 cm from the marginal gingiva in relation to the left maxillary 1st premolar region till the mid palatine region. The mass was asymptomatic, firm with a smooth surface. Overlying mucosa was ulcerated. The mass was non tender, non-fluctuant, non-compressible and without any pus or discharge on palpation. (Fig. 1)

After routine preoperative investigations, the case was planned for surgical excision under general anesthesia. Nasotracheal intubation was done. The extraoral skin was prepared using povidone-iodine solution. Local anesthesia with 1:80,000 adrenaline was infiltrated around the mass to achieve vasoconstriction. Wide excision of the mass including the periosteum was done with curettage of the underlying bone.(Fig. 2) Haemostasis was achieved with the help of electrocautery. Excised mass was sent for histopathologic examination.(Fig. 3) The residual site was covered with an acrylic plate and stabilized with the wiring. Postoperative medications were prescribed. Healing was uneventful. Histopathologic reports showed the presence of myoepithelial cells and ducts lined by cuboidal cells confirming the diagnosis of pleomorphic adenoma. (Fig. 4) The patient was followed up at monthly intervals up to 1 year with no signs of recurrence.

Discussion

Neoplasms affecting the minor salivary glands account for 20-40 % of all salivary gland tumors, precisely 22 %, according to Spiro.^{1,3} Mucoepidermoid carcinoma is the most common malignant tumor with pleomorphic adenoma as its benign counterpart.⁷ Clinically it presents as a slow growing, asymptomatic, firm mass. When originating in the minor salivary glands, it occurs on the soft and hard palate due to the

presence of highest concentration of salivary glands.¹

It is the most common of the salivary gland tumor occurring at any age but mostly affects young and middle-aged adults between ages of 30-60 years with a slight female predilection. Palatal tumors are usually smooth, dome-shaped masses which are well circumscribed and encapsulated. The lack of complete encapsulation is more common for minor glands.² Though benign, it exhibits aggressive behavior locally due to lack of fibrous capsule leading to invasion and erosion of adjacent bone.^{3,7}

The diagnostic modalities include imaging and FNAC. Maxillary x-rays reveal radiolucency and mottled appearance.⁷ CT or MRI scanning is mandatory in cases of lesions having ill-defined margins to rule out the involvement of the nasal or antral cavity. FNAC is a valuable diagnostic test. Its accuracy is greater than 96 % with a sensitivity of 88- 98 % and specificity of 94 % for benign tumors. Frozen sections are 93 % accurate when performed at surgery.⁵

It is an epithelial tumor of complex morphology, possessing epithelial and myoepithelial elements arranged in varieties of patterns and embedded in mucopolysaccharide stroma. Formation of the capsule is a result of fibrosis of the surrounding salivary parenchyma which is composed of the tumor and is referred to as false capsule.⁶

Tumors of hard palate are usually excised down to the periosteum including the overlying mucosa with 1 cm clinical margins at the periphery. If the tumor extends to the soft palate, excision of the fascia over the muscles of soft palate recommended.⁶

Pleomorphic adenoma does not recur after adequate surgical excision. Reasons for recurrence include incomplete excision, seeding, cutting through the extracapsular

projections, or rupture of the capsule and accidental seeding of tumor cells.⁶

Conclusion

Careful history, patient evaluation, histopathological and radio imaging is advised for pleomorphic adenoma of minor salivary glands. Complete surgical excision of the lesion is the treatment of choice and lowers the risk of recurrence. However, recurrence and malignant transformation is a major concern making long-term follow-up a necessity.

References

1. Rahnama M, Orzędą-Koszel U, Czupkałło L, Łobacz M. Pleomorphic Adenoma Of The Palate: A Case Report And Review Of The Literature. *Wspolczesna Onkol* 2013; 17(1): 103-106
2. Lenka SP, Padhiary SK, Subudhi SK, Pathak H, Sahoo S. Pleomorphic Adenoma of Hard Palate: A Case Report. *International Journal of Scientific and Research Publications* 2013; 3(1): 1-3
3. Moghe S, Pillai AK, Prabhu S, Nahar S, Kartika UK. Pleomorphic Adenoma of the Palate: Report of a Case. *IJSS* 2014; 2 (1): 54-56
4. Singh OP, Jaiswal I, Devi HP, Singh GR, Maibam MS, Khundrakpam R. Pleomorphic Adenoma Of Soft Palate: Report Of A Case With Brief Review Of Literature. *IOSR Journal of Dental and Medical Sciences* 2016; 15, 14-19.
5. Bajia SM, Srivastava T, Viswanathan B, Jayaram RT, Vijayashree MS, Srinivasan SB Pleomorphic Adenoma Of The Palate: Presentations And Management. *Res Otolaryngol* 2016; 5(1): 16-19
6. Sharma Y, Maria A, Chhabria A. Pleomorphic Adenoma Of The Palate. *Natl J Maxillofac Surg.* 2011; 2: 169–171.
7. Sharma S. Pleomorphic Adenoma of Hard Palate: A Case Report and Review of Literature. *IJSS Case Reports & Reviews* 2015; 1: 12-14.

Figures and Legends

Fig 1. Intra-oral view of the pathology.

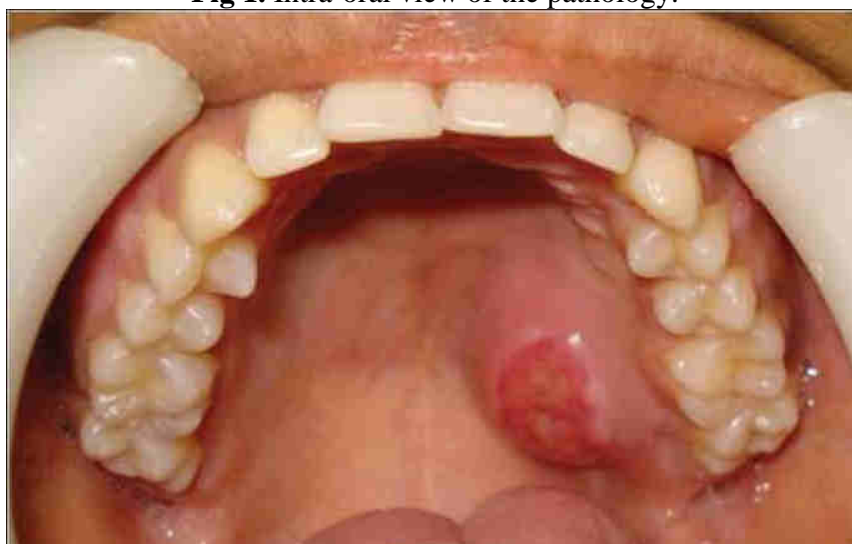


Figure 2: Excision of the masses with wide margins and to the bone.

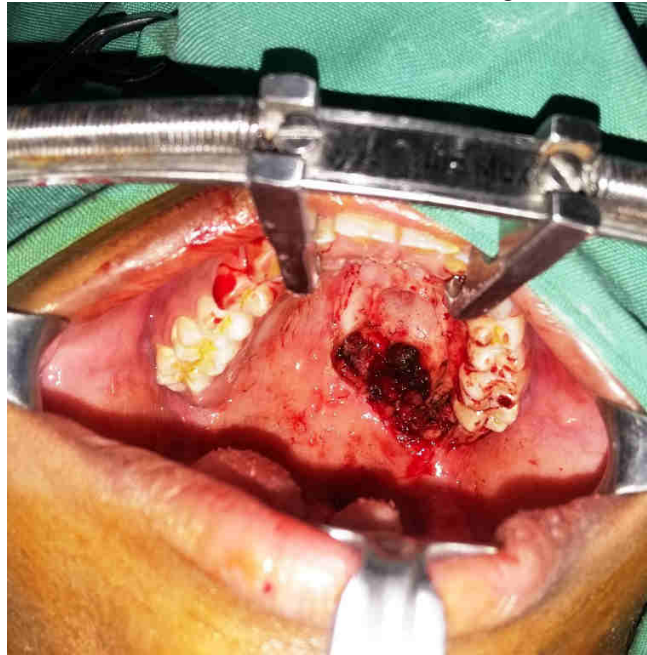


Fig 3: Excised specimen

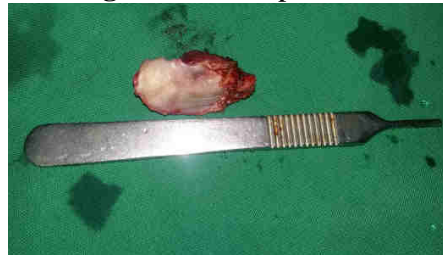


Fig 4: Histopathology confirming pleomorphic adenoma

