

**TUBERCULOSIS OF STERNOCLAVICULAR JOINT: A RARE PRESENTATION OF  
COMMON DISEASE**

**Dr Bhupen Barman<sup>1</sup>, Dr Tony Ete<sup>2</sup>, Dr Ojing Komut<sup>3</sup>, Dr Hage Nobin<sup>4</sup>, Dr Sumantra Mondal<sup>5</sup>**

*1. Assistant Professor, Department of General Medicine, North Eastern Indira Gandhi Regional Institute of Health and Medical Sciences, Shillong, Meghalaya.*

*2. Senior Resident, Department of General Medicine, 3. Senior Resident, Department of Surgery North Eastern Indira Gandhi Regional Institute of Health and Medical Sciences, Shillong, Meghalaya.*

*4. Senior Resident, Department of Pathology, North Eastern Indira Gandhi Regional Institute of Health and Medical Sciences, Shillong, Meghalaya.*

*5. Resident, Department of Medicine, IPGMER and SSKM Hospital, Kolkata*

Submitted on: June 2015

Accepted on: July 2015

For Correspondence

Email ID:

[tonyete14@gmail.com](mailto:tonyete14@gmail.com)

**Abstract:**

Tuberculosis of sternoclavicular joint is very rare accounting for 1% of all peripheral tuberculous arthritis. Sternoclavicular joint arthritis is rare and is most often due to staphylococcus aureus. Here we are reporting a case who presented with swelling of right sternoclavicular joint with non specific signs and symptoms later diagnosed to be a case of sternoclavicular joint tuberculosis. He was treated and cured with antitubercular regimen.

**Keywords: Sternoclavicular joint swelling, Cytology, Tuberculosis.**

**Introduction:**

Tuberculosis has been a major cause of morbidity and death worldwide since time immemorial. Osteoarticular involvement of tuberculosis constitutes 10% of extra pulmonary tuberculosis in immunocompetent individuals. Tuberculosis of sternoclavicular joint is very rare accounting for 1% of all peripheral tuberculous arthritis. Patient usually presents with painless or painful swelling around the sternoclavicular joint with or without constitutional symptoms. Diagnosis of this rare manifestation of tuberculosis is difficult because of similar presentation of other arthritis. Conventional roentgenogram is also not much helpful in detecting early

lesion in sternoclavicular joint. However, if diagnosed, response to therapy is good. Here we are reporting a case of tuberculosis of sternoclavicular joint in 34 year old male patient having complained of right sternoclavicular joint swelling. X-Ray of the joint revealed no significant abnormality other than soft tissue changes, definitive diagnosis was made on the basis of the presence of mycobacterium tuberculosis in the histological specimen. The patient responded well to full course of ATT (DOTS). Tuberculosis should be considered in patient with isolated arthritis as differential diagnosis.

**Case:** A 34 year old male presented with fever for one month and swelling on right

sternoclavicular joint for the same duration. He also had complaints of myalgia, arthralgia and generalized weakness. The patient had a history of being treated with multiple courses of antibiotics and non steroidal anti-inflammatory drugs. There was no past history of tuberculosis. On examination patient was febrile. General examination was normal except for an increased pulse rate (PR-110 /minute). Respiratory system, Gastrointestinal system and Cardiovascular system showed no abnormality on systemic examination. There was a red, tender swelling on the right sternoclavicular joint (3x3 cm) with no discharging sinus. Blood reports revealed a Hb- 12.3gm/dl, Total leukocyte count - 10000 /cumm, platelet count- 2.3 lakhs, ESR- 84 mm in 1<sup>st</sup> hr. Renal function test and liver function test were within normal limit. Blood for HIV-1 and HIV-2 were negative. Chest X ray was normal and Sonography abdomen revealed no significant abnormality. Fine needle aspiration cytology from the swelling showed granulomatous changes and staining for AFB was positive. The patient was started on Antitubercular drugs comprising of Isoniazid, Rifampicin, Ethambutol and Pyrazinamide in intensive phase followed by isoniazid and rifampicin in continuation phase. On follow up after one month the patients' sternoclavicular swelling decreased with significant improvement in other clinical components.

#### Discussion:

Despite the availability of effective diagnostic, preventive and curative treatment, Tuberculosis remains the number one cause of adult deaths by a curable infectious disease globally. The lung is the primary site of infection in most cases. Extra pulmonary tuberculosis is commonly consequence or accompaniment of pulmonary tuberculosis. Skeletal tuberculosis constitutes around 10% of the

extra pulmonary tuberculosis in immunocompetent individuals. The most frequently involved site is the vertebral body (lower thoracic and upper lumbar) followed by involvement of hip joint, knee joint, foot bones, elbow joint, hand bones and shoulder joint. Sternoclavicular septic arthritis is rare and is most often due to staphylococcus aureus.<sup>1</sup> Tuberculosis of sternoclavicular joint is very rare, accounts for only 1 to 2% of all cases of peripheral tuberculous arthritis.<sup>2</sup> In a series of 75 cases tuberculosis of upper limb joints, tuberculosis of the sternoclavicular joint was reported in only one case.<sup>3</sup> There are some anecdotal case reports of tuberculosis of sternoclavicular joint from across the globe. The rarity of occurrence of tuberculosis of sternoclavicular joint can be explained by the peculiar blood supply of the joint.<sup>4</sup>

The disease usually starts in the bone at the medial end of the clavicle and presents as painless or painful swelling. The swelling is slowly progressive in nature and it may or may not be associated with constitutional symptoms. Diagnosis is often difficult because of similar presentation in acute pyogenic arthritis, rheumatoid arthritis, multiple myeloma and metastasis. Poor response to antibiotic therapy may give a clue to underlying tuberculosis. If diagnosis of sternoclavicular tuberculosis goes unrecognised, it may lead to formation of cold abscess or sinus. Eventually there may be compression or erosion of the surrounding large blood vessels at the base of the neck and migration of tuberculous abscesses to the mediastinum. Conventional roentgenogram will not help in the diagnosis as the sternoclavicular joint is not well visualised on routine X-Ray. Magnetic resonance imaging (MRI) is probably the best imaging modality for early detection and diagnosis of these perplexing cases.<sup>5</sup> Definitive diagnosis of sternoclavicular tuberculosis could be made on the basis of

isolation of mycobacteria in the histological specimen. With early diagnosis and treatment prognosis of this rare form of tuberculosis is very good.

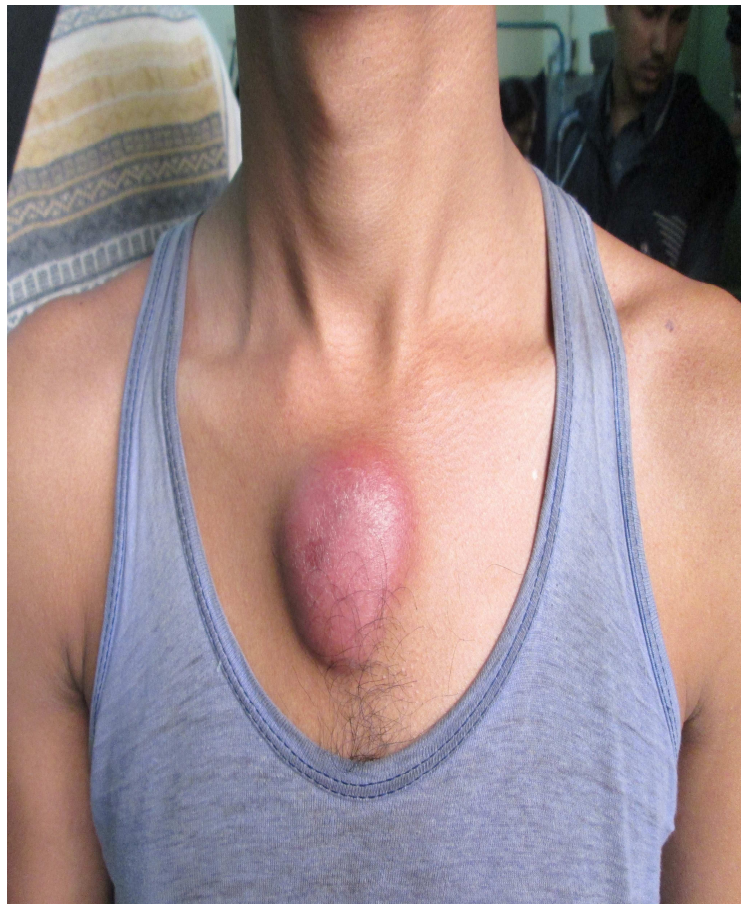**Conclusion:** Tuberculosis of sternoclavicular joint is extraordinary rare and can raise diagnostic problems.

**References:**

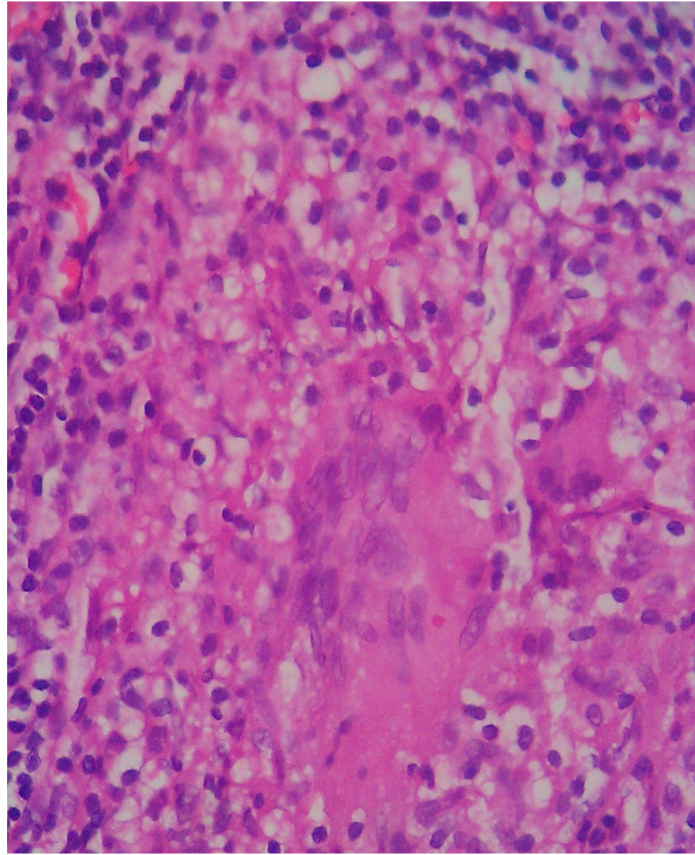
- 1) Ross JJ, Shamsuddin H. Sternoclavicular septic arthritis: review of 180 cases. *Medicine (Baltimore)*. 2004 May; 83(3):139-48.
- 2) Bezza A, Niamane R, Benbouazza K, el Maghraoui A, Lazrak N, Kettani M, Missaoui A, Bensabbah R, Rhazali L, Hassouni F, Mohattane A, Hajjaj-Hassouni N. Tuberculosis of the

sternoclavicular joint. Report of two cases. *Rev Rhum Engl Ed*. 1998 Dec;65(12):791-4.

- 3) Martini M, Benkeddache Y, Medjani Y, Gottesman H. Tuberculosis of the upper limb joints. *Int Orthop*. 1986;10(1):17-23.
- 4) Sy MH, Konaté I, Gassama A, Kane A, Sèye SI. [Monoarticular sternoclavicular arthritic tuberculosis: a proposal and an observation]. *Int J Tuberc Lung Dis*. 2000 May;4(5):486-7.
- 5) Khan SA, Zahid M, Asif N, Hasan AS. Tuberculosis of the sternoclavicular joint. *Indian J Chest Dis Allied Sci*. 2002 Oct-Dec;44(4):271-3.



**Figure 1:** Right sternoclavicular joint swelling.



**Figure 2:** Fine needle aspiration cytology showing granulomatous changes in the aspirated material.