

Case Report

LYMPHEDEMA IN DENGUE FEVER – AN UNREPORTED CASE

Ching Soong Khoo^{1*}, Wan Yi Leong¹, Rosaida Md Said¹, Suguna Raman², Pushpagandy Ramanathan², Petrick Periyasamy³

1. Department of Internal Medicine/ Ampang Hospital/ Jalan Mewah Utara, Taman Pandan Mewah, 68000 Ampang, Selangor, Malaysia

2. Department of Radiology/ Ampang Hospital/ Jalan Mewah Utara, Taman Pandan Mewah, 68000 Ampang, Selangor, Malaysia

3. University Kebangsaan Malaysia Medical Centre/ Jalan Yaacob Latif, Bandar Tun Razak, 56000 Cheras, Kuala Lumpur, Malaysia

Submitted on: October 2015
Accepted on: October 2015
For Correspondence
Email ID:
chingsoongkhoo@gmail.com

Abstract

Dengue fever is a neglected tropical disease, which is rearing its ugly head in increasing numbers of both morbidities and mortalities in Malaysia. As of August 18, 2015, a total of 76819 dengue cases and 212 dengue deaths have been reported for 2015 according to Malaysian health officials [1]. Atypical presentations of dengue fever are also on the rise, which are underreported or unrecognized due to lack of awareness [2,3,4]. Lymphedema complicating dengue fever has not been reported in any literature. We detail this case to highlight the varied manifestations of dengue fever.

Keywords: Dengue fever, lymphedema

Introduction

According to the World Health Organization (WHO), dengue fever is most commonly an acute febrile illness defined by the presence of fever and two or more of the following, retro-orbital or ocular pain, headache, rash, myalgia, arthralgia, leukopenia, or hemorrhagic manifestations. It is a systemic and dynamic disease [5]. Dengue fever is a vector-borne disease transmitted by several species of mosquito within the genus *Aedes*, principally *A. aegypti*. Treatment of dengue fever is mainly supportive and there is no vaccine available at present.

Case Report

A 38-year-old Nepalese gentleman presented to the Emergency Department with fever for three days, arthralgia, myalgia, persistent vomiting, epigastric pain and productive coughs. He had been in Malaysia for ten months and worked as a security guard. He stayed in a dengue-prone area. Upon arrival, he was alert, conscious, and not tachypneic. His height and weight were 1.67m and 65kg respectively. He was febrile at 38.4 degrees Celsius. Otherwise, his other vital signs were stable. He had bibasal crackles and widespread expiratory rhonchi on respiratory examination. Cardiovascular examination revealed no

murmurs and no signs of pulmonary hypertension. Other system examination was unremarkable and he did not have any signs of plasma leakage. His blood investigations upon arrival were as follows: positive dengue non-structural protein-1 (NS1 antigen) on Dengue Combo Rapid Test Kit, hemoglobin 13.5g/dL, hematocrit 35.1%, white blood cell $4.1 \times 10^9/L$, platelet $139 \times 10^9/L$, albumin 39g/L, alanine transaminase (ALT) 44U/L, aspartate transaminase (AST) 91U/L, activated partial thromboplastin time (APTT) 45.8 seconds, urea 2.8mmol/L, creatinine 112 $\mu\text{mol/L}$. Dengue IgM was detected on day five of illness and blood films for malarial parasites were repeatedly negative. Electrocardiogram showed sinus rhythm. His chest film was normal. He was then admitted with dengue fever in febrile phase with warning symptoms (persistent vomiting and abdominal pain) and acute bronchitis. He was managed with intravenous fluids, Augmentin and nebulised Combivent.

He had an uneventful stay in the ward till he reached critical phase on day six of illness. Apart from tachycardia, he was tachypneic requiring nasal prong oxygen support. Plasma lactate crept up to 3.2mmol/L. We also noticed non-pitting edema in his lower limbs since the day before (day five of illness). Breath sound was reduced on the right base. He was subsequently transferred to the High Dependency Ward (HDU) for compensated dengue shock syndrome with right pleural effusion and pneumonia. Antibiotics were upgraded to ceftriaxone and azithromycin.

This gentleman remained stable with nasal prong oxygen at the HDU. He was not transfused and was not on any vasopressors. On day nine of illness (recovery phase), he was transferred back to the dengue ward. He was stable and had no warning symptoms. His chief concern was the leg swelling and

heaviness, making ambulation difficult. Clinical examination revealed non-pitting edema up to bilateral knees. They were neither tense nor tender. No skin changes, ulcerations or varicose veins were found on clinical examination. Femoral, popliteal, posterior tibial and dorsalis pedis pulses were well felt. There was no edema in other body parts. He claimed that the swollen legs occurred on day six of illness (critical phase) and this had never happened previously. There was no recent history of fall or trauma to the legs. He had no symptoms of heart failure prior to admission. His creatinine was normalized at $70\mu\text{mol/L}$. ALT and AST peaked at 93U/L and 118U/L respectively. He was not hyperglycemic in the ward with HbA1c 5.5%. His thyroid function test was normal. Microfilariae were not detected on blood films. He had no proteinuria. Results of serological testing for HIV, syphilis, hepatitis B and hepatitis C were negative. Ultrasound revealed minimal right pleural effusion with no pericardial effusion. There were no abdominal mass and ascites too. ECHO was normal with ejection fraction 70%.

Ultrasound Doppler of both lower limbs revealed no evidence of deep vein thrombosis. However, there were bilateral enlarged inguinal lymph nodes and subcutaneous edema of both lower limbs (Figure 1 & 2). The edema was found from bilateral feet up to thighs. We managed him with compressive bandage and leg elevation in the ward. Five days later, he ambulated well and repeated ultrasound was normal (no more enlarged lymph nodes and subcutaneous edema). Calf and thigh were measured at 32cm (from 38cm) and 42cm (from 52cm) respectively upon discharge. He remained well and had no more leg swelling two months later in the clinic for follow-up.

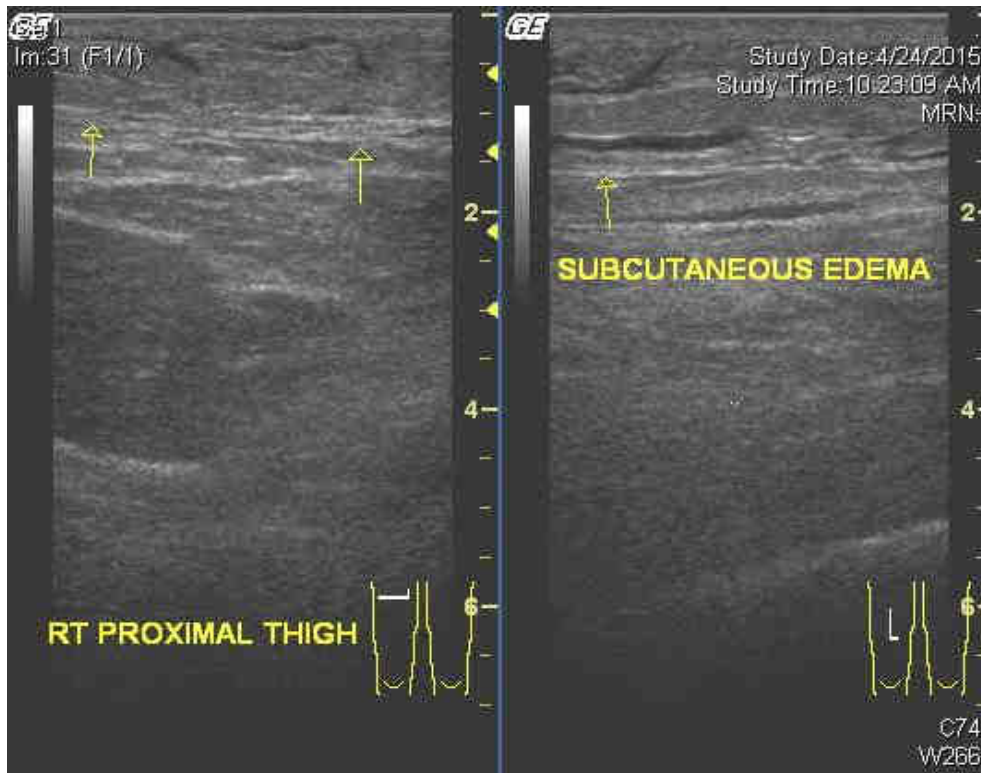


Figure 1. Subcutaneous edema in the right proximal thigh.

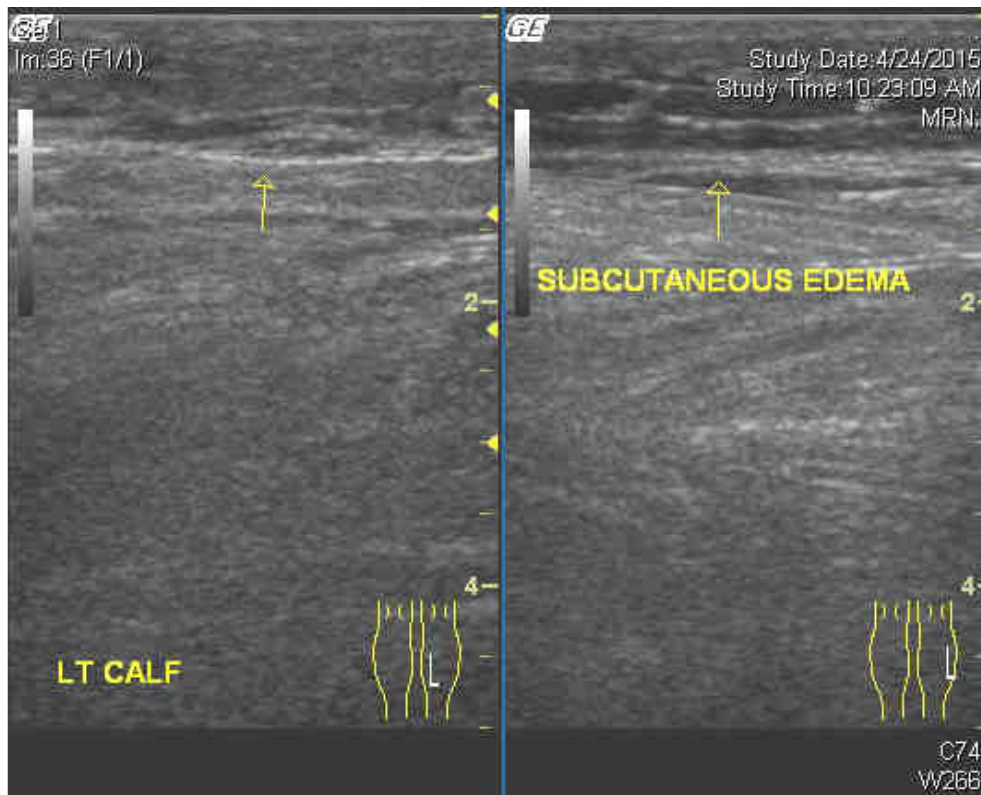


Figure 2. Subcutaneous edema in the left calf.

Discussion

With rapid population growth, tremendous urbanization and inappropriate sanitary measures, incidences of dengue fever have increased exponentially over the years. As of August 1, 2015, the number of dengue cases is 28.6% higher compared with the same reporting period of 2014 in Malaysia according to the Dengue Situation Update by the World Health Organization (WHO). Dengue fever poses a substantial economic and disease burden particularly in Malaysia, which is an endemic country^[6].

One of the problems that clinicians are facing now in treating dengue fever is the increasingly atypical manifestations and complications. Non-pitting edema complicating dengue fever, to our best knowledge, has not been reported in medical literature. Non-pitting edema is defined when indentation does not persist after applying pressure to the swollen area. Its causes include lymphedema, myxedema and lipedema^[7].

Our patient developed bilateral leg swelling on day five of illness (entering critical phase) and resolved nine days later. Common causes of edema have been ruled out in our case such as heart failure, liver failure, nephrotic syndrome, deep vein thrombosis and filariasis^[8]. He was not obese with body mass index 23.3. He did not ingest any drugs known to cause edema. There were no features suggestive of venous insufficiency. His thyroid function was normal. His hepatitis, syphilis and HIV results were non-reactive.

We believe that our patient had lymphedema. Lymphedema is a condition of localized edema due to a compromised lymphatic system, which impedes and diminishes lymphatic return. Lymphedema

is classified as primary (genetic) or secondary (acquired) lymphedema^[9]. Primary lymphedema can further be classified into congenital, precox and tarda^[10]. Primary lymphedema is caused by either congenital hypoplasia or aplasia of the peripheral lymphatics; or valvular incompetence. In secondary lymphedema, the lymphatic failure is caused by either acquired blockade of the lymph nodes or disruption of the lymphatic channels. Its causes are summarized in table 1^[10].

In filariasis, the adult worms cause damage to the lymph vessels either by dilating them or inhibiting their contractility^[11]. The common etiological agents for lymphatic filariasis are *Wuchereria bancrofti*, followed by *Brugia malayi* and *Brugia timori*. Recurrent skin infections, such as cellulitis and erysipelas cause lymphedema via lymphangitis and lymphadenitis^[12]. Lymphedema, mainly in the acral distribution, is seen in chikungunya fever^[13]. Herpes simplex virus type 2 has been found to be associated with lymphedema^[14,15].

Dengue fever can cause generalized lymphadenopathy^[16]. Lymphadenopathy is common^[17] and Halstead SB et al. reported 26-50% of lymphadenopathy in dengue fever. Our patient developed bilateral inguinal lymphadenopathy as evidenced by ultrasound. We believe that lymphedema in this case is due to the obstruction from the enlarged inguinal lymph nodes. Subsequent ultrasound did not reveal any more enlarged inguinal lymph nodes after the lymphedema had subsided.

Our case demonstrates that compressive bandage and elevation of the legs are successful in treating lymphedema in dengue fever.

| Blockade at the level of the lymph node | Disruption or obliteration of lymphatic channels |
|--|---|
| <p>Regional lymph node dissection: Axillary (post-mastectomy lymphedema) Pelvic and para-aortic (leg and groin lymphedema) Neck (head and neck lymphedema)</p> <p>Neoplastic disease: Hodgkin lymphoma Metastatic cancer Prostate cancer Cervical cancer Breast cancer Melanoma</p> | <p>Surgery, e.g. ilio-femoral bypass Direct injury, e.g. trauma of the medial aspect of the thigh Radiation-induced fibrosis Neoplastic infiltration of lymphatic channels Rheumatoid arthritis Filariasis Recurrent infection, e.g. erysipelas</p> |

Table 1. Secondary lymphedema.

Conclusion

This is the first unreported case of lymphedema in dengue fever, highlighting the varied manifestation of dengue fever. The pathogenesis of it is probably due to the obstruction from the enlarged inguinal lymph nodes, which are commonly seen in patients with dengue fever. Compressive bandage and leg elevation are shown to be effective in our case in managing lymphedema in dengue fever.

References

1. iDengue. 2015. <http://idengue.remotesensing.gov.my/idengue/index.php> (Accessed 2015-08-18).
2. Gulati S, Maheshwari A. Atypical manifestations of dengue. *Trop Med Int Health*. 2007 Sep;12(9):1087-95. doi:10.1111/j.1365-3156.2007.01891.x.
3. Satya Sudhish Nimmagadda, Chakrapani Mahabala, Archith Bolor, Pavan Manibettu Raghuram, Akshatha Nayak U. Atypical Manifestations of Dengue Fever (DF) – Where Do We Stand Today?. *J Clin Diagn Res*. 2014 Jan; 8(1):71–73. doi:10.7860/JCDR/2014/6885.3960.
4. Nataraj Gangasiddaiah, Nagaraj Nanjundaiah. Dengue fever: atypical manifestation. *Int J Res Med Sci*. 2014 Nov;2(4):1804-1806. doi:10.5455/2320-6012.ijrms201411119.
5. WHO. *Dengue Guidelines for Diagnosis, Treatment, Prevention and Control*, New edition, 2009.
6. Donald S. Shepard, Eduardo A. Undurraga, Yara A. Halasa. Economic and Disease Burden of Dengue in Southeast Asia. *PLoS Negl Trop Dis*. 2013 Feb; 7(2): e2055. doi:10.1371/journal.pntd.0002055.
7. Kathryn P. Traves, James S. Studdiford, Sarah Pickle, Amber S. Tully. *Edema: Diagnosis and Management*. *Am Fam Physician*. 2013 Jul 15;88(2):102-110.
8. John W. Ely, MD, MSPH; Jerome A. Osheroff, MD; M. Lee Chambliss, MD, MSPH; Mark H. Ebell, MD, MS. Approach to Leg Edema of Unclear Etiology. *J Am Board Fam Med*. 2006;19(2):148-160.
9. Browse NL, Stewart G. Lymphoedema: pathophysiology and classification. *J Cardiovasc Surg (Torino)* 1985 Mar-Apr;26(2):91-106.
10. Andrzej Szuba, Stanley G Rockson. Lymphedema: classification, diagnosis

- and therapy. *Vascular Medicine* 1998; 3:145–156.
11. R. K. Shenoy. Clinical and Pathological Aspects of Filarial Lymphedema and Its Management. *Korean J Parasitol.* 2008 Sep; 46(3):119–125. doi:10.3347/kjp.2008.46.3.119.
 12. Rose Cooper, Richard White. Cutaneous infections in lymphedema. *Journal of Lymphoedema*, 2009, Vol 4, No 1:44-48.
 13. Debabrata Bandyopadhyay, Sudip Kumar Ghosh. Mucocutaneous manifestations of chikungunya fever. *Indian J Dermatol.* 2010 Jan-Mar; 55(1): 64–67. doi:10.4103/0019-5154.60356.
 14. Fletcher PG, Sterling JC. Recurrent herpes simplex virus type 2 infection of the hand complicated by persistent lymphoedema. *Australas J Dermatol.* 2005 May;46(2):110-3.
 15. Butler DF, Malouf PJ, Batz RC, Stetson CL. Acquired lymphedema of the hand due to herpes simplex virus type 2. *Arch Dermatol.* 1999 Sep;135(9):1125-6.
 16. Abdullah A. Abba, Mohamed Z.Khalil. Clinical Approach to Lymphadenopathy. *JK-Practitioner* 2011;16(1-2):1-8.
 17. Duane J Gubler. Dengue and Dengue Hemorrhagic Fever. *Clin. Microbiol. Rev.* July 1998 vol. 11 no. 3 480-496.
-