

**UNUSUAL LUNG INVOLVEMENT WITH ECHINOCOCCUS GRANULOSUS  
ACCOMPANIED BY MYCOBACTERIUM TUBERCULOSIS: A CASE REPORT**

**Mohammad Samet<sup>1</sup>, Oldooz Aloosh<sup>2</sup>, Shirin Karimi<sup>1</sup>, Masoud Rahimian<sup>1</sup>, Naghmeh Kohansali<sup>3</sup>, Ahmad Zare Banadkooki<sup>4</sup>, Jamshid Ayatollahi<sup>5</sup>, AliReza Esmaeili<sup>6</sup>, Seyed Hossein Shahcheraghi<sup>5\*</sup>**

1. Department of Internal Medicine, Shahid Sadoughi University of Medical Sciences, Yazd, Iran
2. Fellowship of Pulmonology, Shahid Beheshti Medical University, NRITLD, Tehran, Iran
3. National Research Institute of Tuberculosis and Lung Disease, Masih Daneshvari Hospital, Shahid Beheshti University of Medical Science, Tehran, Iran
4. Medical Student, Shahid Sadoughi University of Medical Sciences, Yazd, Iran
5. Infectious Diseases Research Center, Shahid Sadoughi University of Medical Sciences, Yazd, Iran
6. Department of Emergency Medicine, Shahid Sadoughi University of Medical Sciences, Yazd, Iran

Submitted on: October 2015

Accepted on: January 2016

For Correspondence

Email ID:

shahcheraghih@gmail.com

**Abstract:**

Hydatid disease is caused by *Echinococcus granulosus* and tuberculosis, which is caused by *Mycobacterium tuberculosis*. Both are infectious diseases with worldwide extension that are endemic in particular areas. Some cases of these diseases have been identified in Iran. The most commonly affected organs in hydatid disease are liver and lungs. Typically, in the case of tuberculosis lungs are infected, but other organs may be infected as well. The present case study reports a male patient co-infected with *Echinococcus granulosus* and tuberculosis while his chest X-ray appearance was unusual and serologic test was negative. Despite the fact that hydatid disease and tuberculosis are not rare diseases in specific epidemiologic settings, we found a small number of cases reported related to lung involvement with both of them. This report intends to emphasize the epidemiologic factors, even with unusual lung presentations, that should be taken into account in differential diagnosis of hydatid disease.

**Keywords:** *Echinococcus granulosus*, *Mycobacterium tuberculosis*, Hydatid Disease.

**Introduction:**

*Echinococcosis* and tuberculosis present medical and economic problems worldwide<sup>1</sup>. *Echinococcosis* is classified as hydatid and alveolar cyst disease, with the former type caused by *E. granulosus* and the latter by *E. multilocaris*. Since the usual intermediate hosts for *E. granulosus* are sheep, goats, camels, horses and dogs, hydatid disease is prevalent worldwide<sup>1-3</sup>. Hydatid disease, however, is known as an

endemic disease in Asia, the Mediterranean countries, Africa, New Zealand, Australia, and South Africa<sup>3</sup>. Iran is an endemic zone of hydatid cyst and human cases have referred from different areas<sup>3, 4</sup>. Tuberculosis is one of the first known diseases which have a high mortality rate till now. It is caused by *Mycobacterium tuberculosis* complex<sup>5</sup>. About one third of human population is infected with this microorganism; however, it doesn't mean

that all of them have tuberculosis disease<sup>6</sup>. The most affected organs in tuberculosis are lungs. As well as in one third of tuberculosis cases other organs are affected<sup>7</sup>. Iran was generally classified as a country with low prevalence<sup>6</sup>, but many areas in Iran have the highest epidemiologic rate (more than 100/100000)<sup>6</sup>.

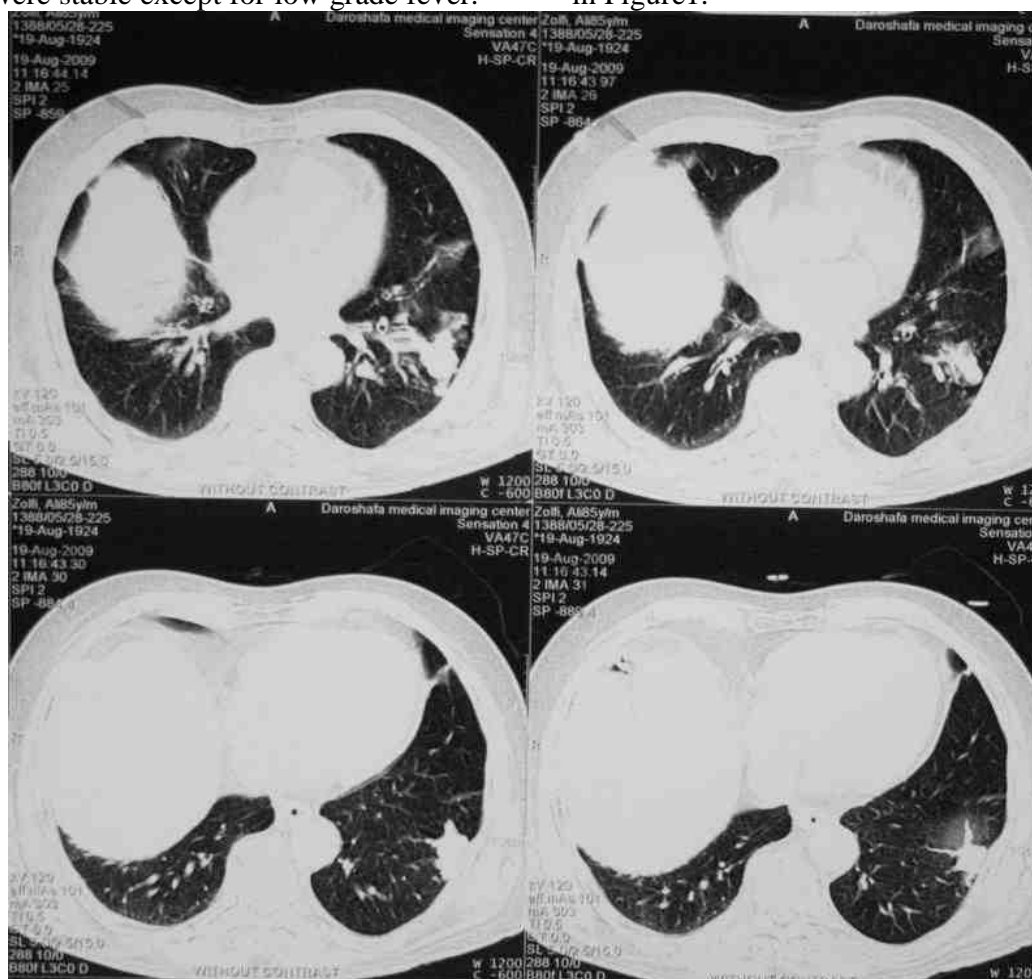
### Case Report:

A 66-year-old male, retired municipal laborer was presented with a 2-month history of dyspnea, orthopnea, productive cough, fever and night sweating. During the course of his illness, the patient lost 10 kg, as well. He was a 10 pack-year smoker. The patient looked ill and cachectic but his vital signs were stable except for low grade fever.

His physical examination revealed scattered rhonchi in basal zones of his left lung and mild pitting edema in both lower extremities.

Organomegaly, lymphadenopathy and digital clubbing were not detected. After initial physical examinations he was hospitalized in order to conduct further detailed medical examinations.

Results from examining the patient's chest X-ray revealed the presence of a left lower lobe discoid density without any sharp borders. Also, spiral Computed Tomography (CT) showed multiple pulmonary parenchyma nodules in the left lower lobe with adjacent mild pleural reaction as shown in Figure1.



**Figure1.** A spiral Computed Tomography (CT) showed multiple pulmonary parenchyma nodules in the left lower lobe with adjacent mild pleural reaction.

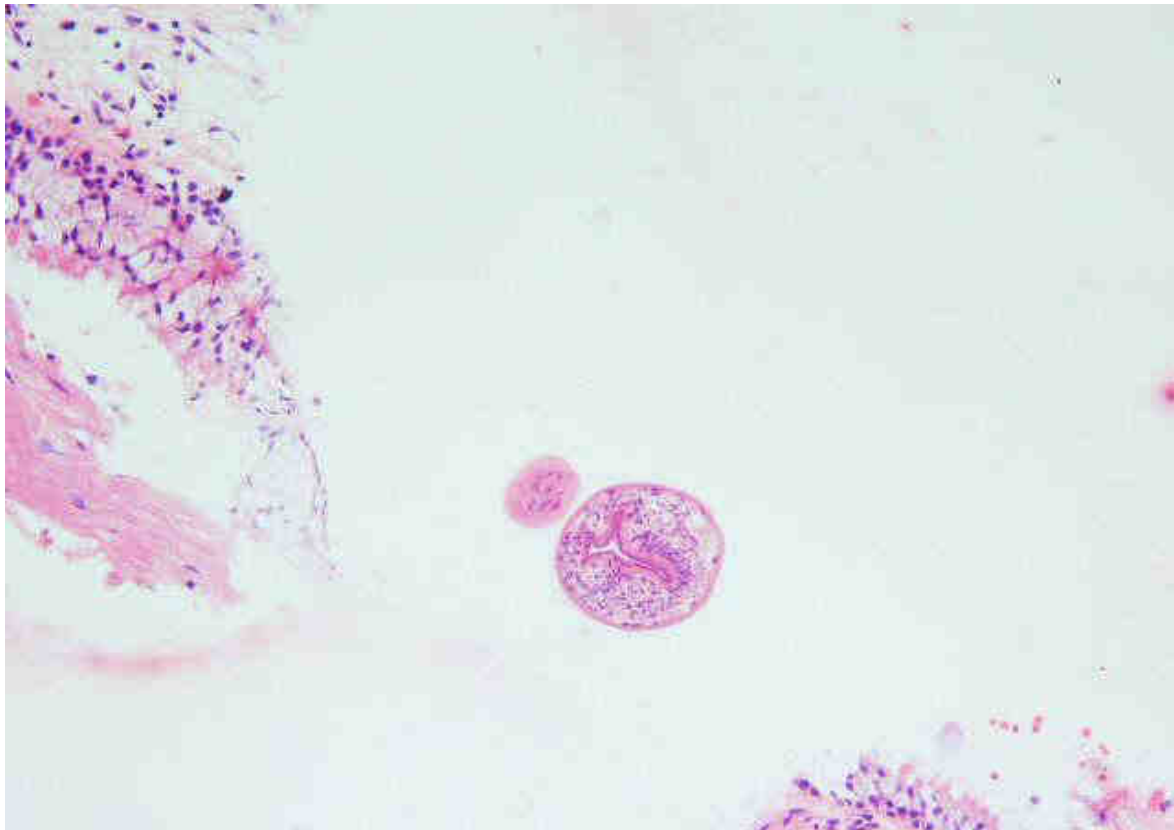
Other imaging studies including abdomen, pelvis, cardiac, and brain were carried out and the test results did not show any abnormal findings.

On the day of hospital admission, skin testing with tuberculin-PPD (Purified Protein Derivatives) was performed and 72 hours later the patient's skin induration was about 9 mm.

The Smear and the culture of the sputum reported negative results for Acid Fast Bacilli (AFB) and other common respiratory pathogens. Serological studies for HCV, HBV, and HIV were also unremarkable. Laboratory studies showed negative serologic test for Echinococcus antibodies. CBC results and other important laboratory findings were as following: WBC=11.6 x

$10^3 /\mu\text{l}$ , Hemoglobin=14.2 g/dl, PLT = $201 \times 10^3 /\mu\text{l}$ , LDH=567 U/L & ESR=61mm/1<sup>st</sup> h.

In the next step the patient was examined by using Fiber Optic Bronchoscopy (FOB). Copious whitish secretion and mucosal edema in the right and the left bronchus were found. Also anthracotic plaque and bronchial narrowing were observed in the orifice of the left lower lobe. Bronchial washing for Acid-Fast Bacilli (AFB) was done. Cytology and bronchial biopsy specimen were taken from the left lower lobe bronchus. The Smear and the culture of the Bronchial washing specimen were positive for AFB and *Mycobacterium tuberculosis*. Scolexes of *E. granulosus* composed of perforated hydatid cysts were observed in bronchial mucosal biopsy specimen as shown in Figure2.



**Figure 2.** Section showed Scolexes of *E. Granulosus*(H&EX10).

The patient underwent medical treatment for both hydatid disease (Albendazol 400 mg twice daily) and *M. tuberculosis* (four drug treatment of tuberculosis including Isoniazid 300mg daily, Rifampin 600mg daily, Pyrazinamide 1500mg daily, Ethambutol 800mg and Vitamin B6 daily). After a month, his follow up examinations revealed a significant improvement in his symptoms and general conditions. His weight also increased by 5 kg during the course of medical treatment.

#### **Discussion:**

Hydatid disease is endemic in areas in which there are contacts between human and dogs and sheep; this situation is common in some parts of Iran, too<sup>2, 3, 6</sup>. Tuberculosis has also spread worldwide and after the significant increase in HIV incidence, mortality rate related to this disease has risen<sup>5, 6</sup>. Infection with *Echinococcus* can cause cystic lesions in any organ particularly in the liver (about 60%) or lungs (25%). In many cases symptoms are absent and infection is detected incidentally by imaging studies<sup>1-3</sup>. Symptoms are usually due to occupying cysts<sup>1</sup>. There are no definitive laboratory tests available for diagnosis of *Echinococcus*. ELISA tests for antigen have high specificity, but in up to one-third of confirmed patients, they are negative<sup>4</sup>. Serology is about 53% sensitive for lung involvement as seronegative lungs involvement in this case. Employing additional recombinant diagnostic antigens and immunogenic peptides may provide more specific and sensitive results<sup>5, 6</sup>. We considered FOB with bronchial brushing and bronchial biopsy, to rule out bronchogenic carcinoma and other differential diagnosis. FOB can confirm the diagnosis in some patients with analysis of endoscopic extraction of hydatid cyst membrane and AFB<sup>7</sup>.

Although asymptomatic hydatid cysts may not need treatment<sup>4</sup>, optimal treatment for symptomatic cysts is surgical resection, but inoperative cysts as the presented case may be treated by medical therapy like Albendazole<sup>8</sup>. A study reported presents the unusual coexistence of tuberculosis and hydatid disease in an adult male and its subsequent diagnosis and management. Blood investigations were normal except for a mildly elevated total leucocyte count of 12,000/ cumm. Sputum was negative for AFB<sup>9</sup>. Another study reported pulmonary hydatid cyst and tuberculosis in a twenty-year-old male patient. In his radiology, on the right lung anterobasal segment uniformly bounded, thick-walled cavity with heterogeneous density in the size of ~ 4x5 cm and next to it, nodular infiltrating views have been found<sup>10</sup>.

#### **Conclusion:**

In any case that tuberculosis is as an atypical form, we should think about other diseases and especially in endemic areas should think about hydatid cyst accompanied by tuberculosis.

#### **References:**

1. Wahlers K, Menezes CN, Romig T, Kern P, Grobusch MP. Cystic echinococcosis in South Africa: the worst yet to come? *Acta Trop* 2013; 128 (1):1-6.
2. Mohosen S, Mirhosseini F, Parsaiyan Z, Fakhri M. A case of cardiac hydatidosis: role for transesophageal echocardiography in evaluating bilateral pulmonary nodules. *Pneumologia* 2013; 62 (2):110-2.
3. Aghajanzadeh M, Aghajanzadeh G, Ebrahimi H, Jahromi SK, Maafi AA, Massahnia S. One stage operation for five giant hydatid cysts of both lungs and liver in a 20-year-old female. *Tanaffos* 2012; 11 (3):52-4.
4. Vismarra A, Mangia C, Passeri B, et al. Immuno-histochemical study of ovine cystic echinococcosis (*Echinococcus granulosus*) shows predominant T cell infiltration in established cysts. *Vet Parasitol* 2015; 209 (3-4):285-8.

“Unusual lung involvement with *Echinococcus granulosus* accompanied by mycobacterium tuberculosis: A case report”

5. Yang YR, Gray DJ, Ellis MK, Yang SK, Craig PS, McManus DP. Human cases of simultaneous echinococcosis and tuberculosis - significance and extent in China. *Parasit Vectors* 2009; 2 (1):53.
  6. Sadrizadeh A, Haghi SZ, Masuom SH, Bagheri R, Dalouee MN. Evaluation of the effect of pulmonary hydatid cyst location on the surgical technique approaches. *Lung India* 2014; 31 (4):361-5.
  7. Lotfi AR, Zarrintan S, Naderpour M, et al. Primary hydatid cyst of the right maxillary sinus: a case report. *Iran J Otorhinolaryngol* 2014; 26 (77):257-61.
  8. Akbulut S, Yavuz R, Sogutcu N, et al. Hydatid cyst of the pancreas: Report of an undiagnosed case of pancreatic hydatid cyst and brief literature review. *World J Gastrointest Surg* 2014; 6 (10):190-200.
  9. Abraham VJ, Mohan Mathur R, Sisodia A, Devgarha S, Yadav A. Coexistent pulmonary hydatid disease and tuberculosis in an adult male. *Egyp J Chest Dis Tuberc* 2013; 62: 651–653.
  10. Akkaş Y, Katrancıoğlu O, Şahin E. Coexistence of pulmonary tuberculosis and hydatid cyst. *Cumhuriyet Tıp Derg* 2011; 33: 483-486.
-