

**AN EVALUATION OF THE PREVALANCE OF CORACO CLAVICULAR JOINT IN HUMANS BY OSTEOLOGICAL AND RADIOLOGICAL STUDIES IN DELHI AND NCR REGION**

**Dr. Nisha Kaul**

*Professor of anatomy, Santosh Medical College, Ghaziabad, Uttar Pradesh, india*

Submitted on: April 2016  
Accepted on: May 2016  
For Correspondence  
Email ID:  
nishakaul.nk@gmail.com

**Abstract**

**Introduction:**

The human pectoral girdle has been found to have rarely an anomalous plain synovial joint called Coraco clavicular joint; besides three conventional anatomical articulations. It is a rare articulation between conoid tubercle of clavicle and superior surface of the horizontal part of the coracoid process of the scapula.

**Aim:** The aim of our study is to find the prevalence of entity ‘the coraco clavicular joint’ in Delhi and NCR region to understand the pathogenesis and correlate our findings with various conditions of unknown etiology like arm & shoulder joint pain, features of brachial plexus compression, thoracic outlet syndrome and painful restricted arm movements, thereby providing appropriate medical and surgical treatment.

**Material and Method:** The study was conducted on dried human clavicles (150 in number) and radio graphs of chest and shoulder joint (AP view) /CT Scan Chest of adult humans (300 in numbers) for evidences of presence of coraco clavicular joints.

**Results:** 16% of the dried clavicles and 14.6% of radiographs/ CT Scan Chest showed evidence of the presence of coraco clavicular joint.

**Discussion & Conclusion:** The presence of coraco clavicular articulation was detected in early 1861. Various factors leading to the Ccj formation include occupational stresses, old age changes, genetic factors, congenital presence of the joint and primary pathological changes in coracoid process of scapula and conoid tubercle of clavicle. Most of the times, Ccj is asymptomatic, being diagnosed incidentally or it may be symptomatic presenting in various forms. Hence Ccj entity finds an important place in differential diagnosis of arm pain and associated conditions.

**Keywords:** Brachialgia, Coraco Clavicular Joint, dry clavicle, radiograph of chest and shoulder/ CT scan Chest, Delhi NCR region,

## Introduction

The human pectoral girdle formed by clavicle and scapula, consists of three anatomical articulations: 1. Glenohumeral joint, 2. Acromio clavicular joint, 3. Sterno clavicular joint<sup>(1)</sup>. In addition, the conoid tubercle of clavicle and the coracoid process of scapula are connected to each other only by a strong coraco clavicular ligament<sup>(1)</sup>; there being normally a gap of 13 mm between the two processes<sup>(2)</sup>.

Rarely an articulation called ‘coraco clavicular joint’ (Ccj) is formed as an anomalous diarthrosis between conoid tubercle of clavicle and superior surface of the horizontal part of the coracoid process of the scapula<sup>(3, 4)</sup>. The evidence of the presence of this rare anomaly has been extensively studied by means of anatomical (dissection), Osteological, and radiological investigations. Most cases are discovered incidentally, with symptomatic variety an exceptional rarity<sup>(5)</sup>.

**TYPE OF JOINT:** Morphologically the coraco clavicular joint is a synovial joint of sliding variety.

**Osteological studies** exhibit its existence as presence of articular facets on the surface of conoid tubercle of clavicle and superior surface of coracoid process of scapula respectively<sup>(3)</sup>.

**Cadaveric (dissection) studies:** The Ccj may be frequently seen existing as cartilage covered articulating facets’ of varying degree of elaboration’ on the clavicle and coracoids process respectively, surrounded by a synovial fibrous capsule. Sometimes an articular cartilaginous disc intervenes across the joint space. Usually the clavicular articular surface surmounts a bony elevation called conoid tubercle, in the region of the attachment of conoid ligament. The articular surface of conoid tubercle is of hyaline cartilage variety and that covering coracoid process is of fibro cartilaginous type. The articular disc intervening between the two bony processes as seen in some cases is also of fibro cartilaginous variety<sup>(6, 7)</sup>. Quite

often the presentation is simply as cartilage covered articulating facets of varying size on the clavicle and coracoid process, without the presence of bony clavicular outgrowth. It has been observed that presence of well-formed conoid tubercle is not a pre requisite for Ccj formation, since well-formed articulations may even without the presence of these processes<sup>(7)</sup>.

**Radiographic appearance** of Ccj appears as a bony outgrowth from the under surface of the clavicle; the outgrowth being triangular with its base oriented towards the inferior surface of the clavicle. The lateral border of this triangle forms an articular surface forming a joint with a tubercle on the dorso medial surface of the coracoids process. These radiographic findings are typical of a joint<sup>(2)</sup>.

Some consider this joint as a normal variant of the pectoral girdle rather than an anomalous or pathological entity<sup>(8)</sup>, where conoid tubercle of clavicle appears enlarged or elongated on the flattened inferior surface of clavicle, approximating with the coracoids process of scapula to form an articulation<sup>(2,8)</sup>. However a close examination of Ccj in dissected human specimens quite often shows variation morphologically as a gradual transition of the joint structure from being a mere bursa to a well developed articulation<sup>(7, 8)</sup> or from a primitive bony articulation to a fully formed diarthrodial joint with a cartilaginous articular surfaces and a joint capsule<sup>(8)</sup>. Similar findings were also observed by Gradoyevitch et al while dissecting cadavers<sup>(9)</sup>. MRI of shoulder region also confirms it to be a true synovial joint having cartilaginous articular surfaces and lined by synovial membrane<sup>(10)</sup>. Kaur & Jitl in their study on clavicles obtained from cadavers of different age groups observed that the facets for Ccj were absent in fetuses, neonates and young children<sup>(11)</sup>. Ccj is a roundish joint, easily observable in primates e.g. Galagomoholi species (a vertical clinger and leaper) where it has

“An evaluation of the prevalence of coraco clavicular joint in humans by osteological and radiological studies in Delhi and NCR region.”

developed in adaptation to different postural behaviors and locomotors practices<sup>(4, 12) & (13)</sup>. It is routinely seen in gorillas and gibbons and is entirely different from ossified coraco clavicular ligament<sup>(12)</sup>. In humans it is thought to be a very rare entity<sup>(3)</sup>; though with the progressing time, it is now more commonly found than previously thought<sup>(7, 14)</sup>.

### **Incidence & geographic distribution:**

The incidence of Ccj is founding varying according to the observations made by various authors.

According to Cockshoot WP, it is more common in Asians than Africans or Europeans with a prevalence of ~10% (range 0.5 -20%)<sup>(15)</sup>. There is an equal male : female distribution<sup>(15)</sup>, in comparison to male :female ratio as 1.4:1 with 42 years as the mean age of presentation according to the figures from database conducted by Singh VK<sup>(5)</sup>.

Gumina S et al reported the incidence as 0.55% to 21 %<sup>(4)</sup>, with Europeans and Africans at a much lower value than Asians<sup>(15)</sup>. According to Sembian U et al, the incidence varies from 0.8% -9.8%<sup>(16)</sup>. Kaur H, Jit I put the incidence as 10.1% in males (bilateral 5.7%, unilateral 4.4%) and 8.3 % in females (bilateral 3.6%, unilateral 4.8%)<sup>(11)</sup>. The incidence on an average is 0.7 %- 10% as per Osteological & dissection studies<sup>(3)</sup> and 0.55% -21% as per radiological studies<sup>(3, 17)</sup>.

**Etiology:** Regarding the formation of Ccj, various theories have been put forward.

Lane WA suggested that Ccj formation was a traumatic sequelae following injury to the shoulder region<sup>(18)</sup>. He also correlated this condition to the occupational stress<sup>(18)</sup>. Ccj may develop secondarily as a result of fixation of the clavicle prompted by fracture of surgical neck of humerus<sup>(3)</sup>. Its development as a result of degenerative changes following ageing is also proposed as the prevalence increases with aging<sup>(19)</sup>. The development of Ccj was also considered as an acquired entity, secondary to changes

in position of the scapula and clavicle with increasing age<sup>(19)</sup>.

According to Kaur & Jit I<sup>(11)</sup> the presence of this joint is neither related to occupation, nor is it congenital. Formation of Ccj later in life is conditioned more by genetic than environmental factors<sup>(11)</sup>. The above theory is further substantiated by the observation of cockshoot WP. According to both, the coraco clavicular joints are genetically determined anatomic variants<sup>(11), (15)</sup> and both genetic and environmental factors are also likely to influence their development<sup>(10)</sup>. Adnan AF believes that the coracoclavicular joints are congenital and often bilateral in their development<sup>(2)</sup>.

Haas W.H.D. De et al also suggests the genetic theory of Ccj formation. Coraco clavicular joint formation is a heritable trait and transmitted as autosomal dominant trait<sup>(20, 21)</sup>. A hypothesis indicating that the joint was infact a hyperosmotic nonmetric skeletal variant was also suggested<sup>(5, 22)</sup>.

Histologically formation of this joint is believed to occur by cartilaginous metaplasia of the trapezoid ligament<sup>(7, 20)</sup>. One study found that individuals with Ccj possessed significantly larger scapular size, longer first ribs, and a longer clavicle than those without this joint<sup>(23)</sup>. They have hypothesized that the above mentioned morphometry may restrict associated movements of scapulae, resulting in the development of this joint<sup>(10)</sup>. It could also be a result of primary pathological changes taking place between coracoid process and conoid tubercle of scapula<sup>(6, 14)</sup>.

**Presentation:** Mostly cases of Ccj formation are asymptomatic, being recognized only on x-ray. When symptomatic, this entity presents as pain in shoulder which is felt in front or on top of shoulder region. Sometimes the pain radiates into the arm<sup>(3)</sup>. Pain produced by Ccj is not only felt over shoulder joint and radiating to arm, but also to breast, neck; persisting during rest and increasing during exercise. Occasional symptoms include

itching of the last four fingers, followed by transient paralysis of the hand<sup>(3)</sup>. Hence though rare, yet Ccj is a well-established cause of shoulder pain and upper limb paresthesia. Brachial plexus involvement is the most common pathophysiological explanation of the symptoms<sup>(5)</sup>. Osteoarthritis may develop in this joint and it may be a source of shoulder pain<sup>(15)</sup>. Besides brachialgia and ipsilateral pain radiation, additional features are limited range of movements of the shoulder with or without painful arc syndrome, swelling & tenderness at the site of Ccj. In advanced cases there may be a fracture of surgical neck of humerus<sup>(5)</sup>. Sometimes Ccj can be palpated under the skin<sup>(2, 14)</sup>. Shoulder pain can also be due to supracoracoid impingement or degenerative changes in anomalous joint in addition to brachial plexus compression<sup>(8, 14)</sup>. It may become painful and symptomatic only in some patients after trauma. Rarely may it be the cause of Thoracic Outlet syndrome<sup>(14)</sup>. The symptoms can be relieved only by resecting the joint<sup>(12)</sup>.

On many occasions, a case of symptomatic Ccj may not be accurately recognized leading to delayed diagnosis or inappropriate management due to lack of evidence, lack of awareness amongst orthopedic community and poor description in orthopedic text books<sup>(5)</sup>. Diagnosis is achieved by x-ray, CTscan<sup>(5)</sup>. Conservative treatment for symptomatic Ccj has low success rate. Surgical intervention in the form of excision of anomalous joint by osteotomy has 100% success rate<sup>(8) & (12)</sup>.

**Aim:** The aim of our study is to find the prevalence of the entity ‘coraco clavicular joint’ in the population of Delhi and NCR region & compare the same with the observations obtained at national and international level. The findings of our research work will ultimately be fruitful to the orthopedicians in correlating & explaining the pathogenesis of various conditions ‘where no definite cause is

found’ with the existence of Ccj; e.g. arm & shoulder joint pain, features of brachial plexus compression, painful restricted arm movements and rarely thoracic outlet syndrome, thereby enabling them to give appropriate medical and surgical treatment to the patients. Any variations in the observations amongst different population can further substantiate the racial and genetic factors as being the basic causes of Ccj formation.

#### **Material and Method:**

The study was conducted on dried human clavicles and radiographs and CTscan chest /shoulder joint (AP view) of adult humans.

#### **Clavicles:**

The clavicles studied were 150 in number. They were procured a) From the dept. of anatomy Santosh Medical College & from medical students of this college b) from dept. of anatomy Saraswati Medical College, Hapur some clavicles were obtained from medical students of some of the medical colleges of Delhi. All bones were randomly collected without any knowledge of age, gender or occupation of the individuals. The bones were thoroughly cleaned, dried and studied for the presence 1) conoid tubercle and 2) an articular facets on conoid tubercles of clavicles by naked eye examination. The presentation of the same is a) either as a gross bony out growth form conoid tubercle or a mildly elevated conoid tubercle, b) the articular facet is well formed and concave or it is flat. The presence of articular facets was confirmed by observing them with a magnifying glass. Those clavicles bearing articular facets were photographed by Sony DSC-W35 digital camera.

**Radiographs/ CTscans:** The number of radiographs /ct scans studied was 300. All of them belonged to adult population. They were obtained (a) from the dept. of radiology Santosh Hospital Ghaziabad (b) from the radiology dept. of Sir Ganga Ram Hospital, New Delhi (c). Some x-rays were also procured from private nursing homes of

“An evaluation of the prevalence of coraco clavicular joint in humans by osteological and radiological studies in Delhi and NCR region.”

Delhi & NCR. The radiographs were randomly selected without any knowledge of gender or information of the ailments for which the x-rays were taken. All radiographs were anterior posterior view of chest including both shoulder joints. The x-ray/CT Scan were studied for any evidence of the existence of coraco clavicular articulation; the evidence being 1).Very close approximation of coracoids process and conoid tubercle with or without the presence of bony outgrowth from conoid tubercle or 2) a minimal distance between the conoid tubercle and coracoids process<sup>(14)</sup>, (the normal distance being 10-13 mm<sup>(2)</sup>). The distance was measured in mm and was categorized as:

- (a) 1 mm or less than 1mm ---strongly positive indicator of Ccj.
- (b) 2-3 mm----Positive indicator of Ccj
- (c) 4-6 mm ----- doubtful cases
- (d) 10 mm & above -----Negative cases

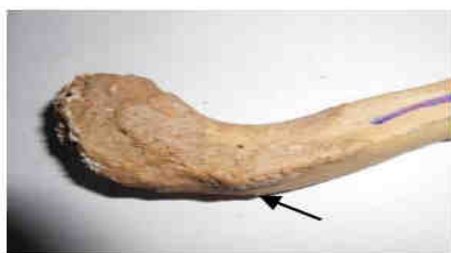Photographs of all positive radiographs / CT scan were taken by Sony digitalcamera.

**Results:**

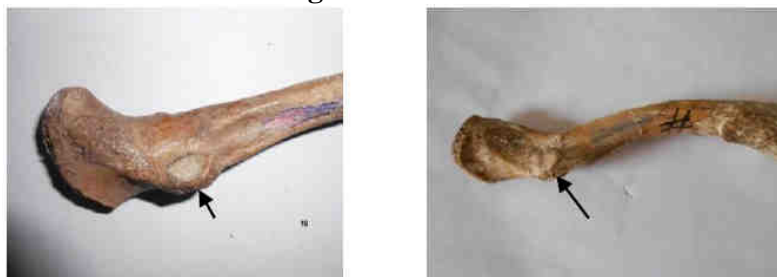**Table 1: Showing observations on clavicles:**

S. No.	Particulars	Numbers	Percentage
1.	No. of Clavicles studied	150	-
2.	No of Positive Specimens	24	16%
2.1	No. of Clavicles with well developed concave facets	09	37.5%
2.2	No. of Clavicles with small flat facets	15	62.5%
2.3	No. of right sided positive specimens	15	62.5%
2.4	No. of left sided positive specimens	9	37.5%
3	No. of Doubtful Specimens	16	10.7%
4.	No. of Negative Specimens	110	73.4%

**PICTURES SHOWING OBSERVATIONS ON CLAVICLES**



**Picture 1: showing conoid tubercle with no facet**



**Picture2: showing elevated conoid tubercles with clear concave facets**

“An evaluation of the prevalence of coraco clavicular joint in humans by osteological and radiological studies in Delhi and NCR region.”



**Picture3: showing flat facets in the region of conoid tubercles on right and left side**

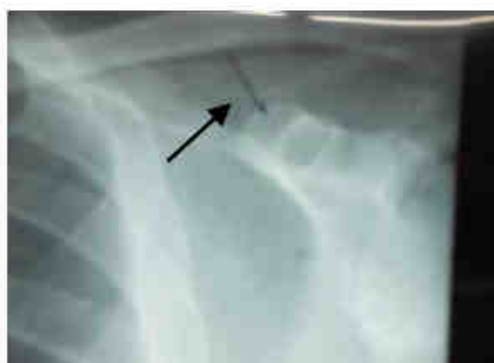

**Picture4: showing doubtful facets**

**Table 2: Showing observations on Radiographs**

S. No.	Particulars	Numbers	Percentage
1.	No. of Radiographs studied	300	-
2.	No of Positive Specimens	44	16%
(i)	No. of Bilateral cases	20	
(ii)	No. of unilateral cases	24	
2.1	No. of cases belonginng to Category (a)	12	24.3%
2.2	No. of cases belonginng to Category (b)	32	75.6%
3	No. of cases belonginng to Category (c)	40	13.3%
4	No. of cases belonginng to Category (d)	216	73%

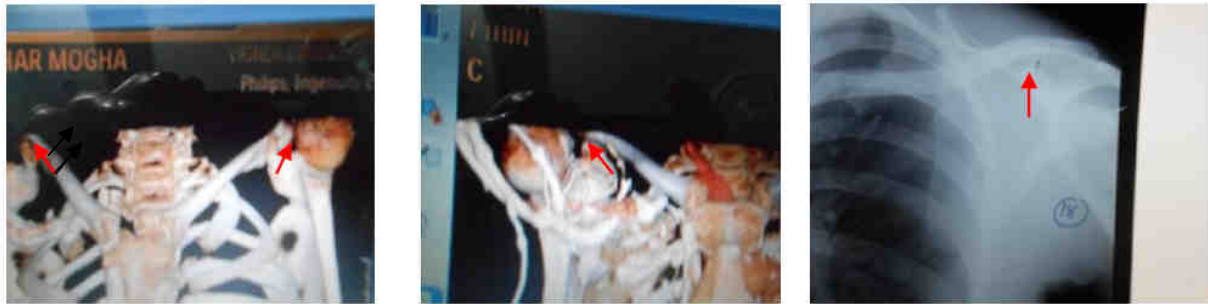**PICTURES SHOWING OBSERVATIONS ON RADIOGRAPHS**



**Picture1: Radiograph showing conoid tubercle and coracoid process separated by a distance of 13 mm (Normal)**

“An evaluation of the prevalence of coraco clavicular joint in humans by osteological and radiological studies in Delhi and NCR region.”

**Picture2: Showing features of Ccj formation(Category a)**



(i)

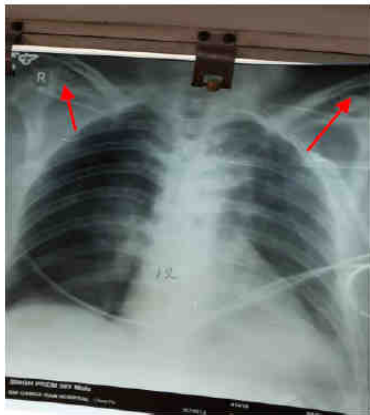
(ii) (Right)

(iii) (Left)

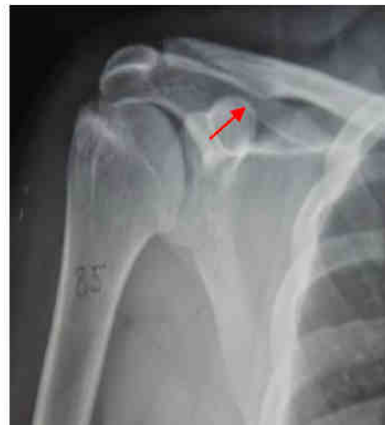**(i) : CT Chest 3D (high resolution) showing conoid tubercle and coracoid process closely approximated to each other (Bilateral);**

**(ii, iii) CT Chest 3D (right sided) & plan x-ray chest (left sided) showing conoid tubercle and coracoid process closely approximated to each other (unilateral)**

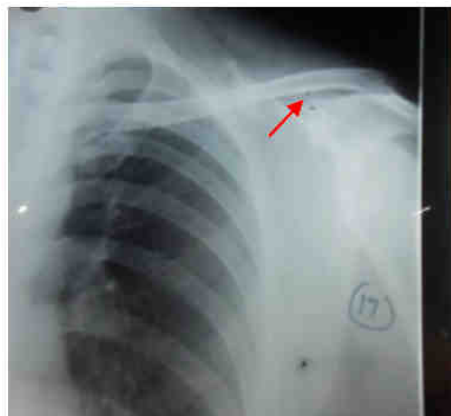
**Picture3: Showing features of Ccj formation (category b)**



iv



v



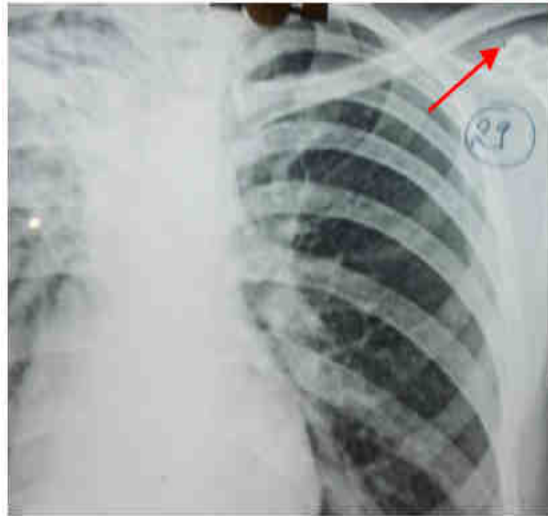
vi

**(iv) Showing conoid tubercle and coracoid process separated by a distance of 2-3 mm (Bilateral)**

**(v, vi) Radiographs (right & left) showing conoid tubercle and coracoid process separated by a distance of 2-3 mm (Unilateral)**



**Picture 4: (Doubtful) (category c)**



**Radiograph showing conoid tubercle and coracoid process separated by a distance of 5 mm**

### Discussion

A lot has been written about Ccj and its presentation. Ccj was first described as early as in 1861 by Gruber<sup>(24)</sup>. Thereafter its presence was observed in people with stressful occupation and its presentation was attributed to alteration in shoulder joint movements or disease of the joint itself<sup>(2,5)</sup>. According to the studies of Libeson (1939), out of 1800 patients studied, only nine patients (0.5%) showed presence of Ccj. Five cases had bilateral Ccj<sup>(25)</sup>. Gradoyevitch B in his study reported 15 cases with positive Ccj, out of which 10 cases were confirmed anatomically and 5 cases radiographically<sup>(9)</sup>. Nutter PD (4F) reviewed 1000 random radiographs of adult shoulders and found 12 (1.2%) cases with Ccj. Six out of 12 cases were bilateral and 11 cases were males<sup>(26)</sup>. An evidence of Ccj in one out of 1800 cases (0.5) has been mentioned by Wertheimer<sup>(27)</sup>.

A 40 year old male having features of right sided brachialgia was diagnosed as having an anomalous joint formation between clavicle and coracoids process on x-ray of right shoulder joint. Surgery was done on the shoulder joint region which confirmed the presence of Ccj. The joint was resected

out and patient was relieved of his symptoms<sup>(28)</sup>.

O J Lewis (1959) in his study on the incidence of Ccj, examined 46 arms of European cadavers by dissection, histological study of the joint tissues and radiological methods. He confirmed the presence of Ccj in these specimens by demonstrating articular cartilage facets on bony elevations of coracoid process and clavicle<sup>(7)</sup>.

A radiographic investigation of both shoulders in 1000 patients with shoulder complaints found this anomaly in twelve patients i.e. 1.2%. In a study on 132 children up to the age of 12 years, two such cases were seen suggesting the incidence to be almost same as in adults<sup>(20)</sup>.

A study on the skeletons of south African population for the study of Ccj by Nalla S revealed that out of 240 skeletons (60 of black race and 180 of white race), only 23 (9.6%) showed presence of Ccj. Out of 23, 6 cases (26.1%) were of whites whereas 17 cases (73.9%) were those of blacks. Male to female ratio was 56.5%:43.5%. Ccj was seen bilaterally in 47.9%, unilateral left sided in 30.4% and unilateral right sided in 21.7%<sup>(23)</sup>.



Cho BP (1998) in an osteological study on 102 dried clavicles and scapulae of Korean cadavers found presence of Ccj in 10 cases (9.8%) with 8.8% bilateral and 1.0% unilateral existence. The joint was found above the age of 40 years<sup>(19)</sup>.

A study conducted by Gumina S. et al on 1020 dry clavicles of Italian origin which dated back to 18<sup>th</sup> and 19<sup>th</sup> century, revealed the presence of Ccj only in 8 clavicles (0.8%). Six clavicles were right sided and two left sided. Six clavicles belonged to males and two clavicles to females. Associated degenerative changes of acromio clavicular and sterno clavicular joint clavicular facets were also noticed in 6 out of the eight clavicles. This suggests the role of Ccj in producing stiffness and degenerative changes in neighbouring joints, probably by reducing the capacity the different stresses applied on them<sup>(4)</sup>.

Adnan (2003) diagnosed bilateral congenital coraco clavicular joint in a 71 year old woman presenting with history of B/L shoulder pain, supra coracoid tenderness with crepitus on deep palpation<sup>(2)</sup>.

Francis Y.P Ma et al reported a patient with h/o left shoulder pain and numbness of limb and a past h/o treated anterior dislocation of shoulder, as a case having symptomatic Ccj. The diagnosis was made only by observing local tenderness above left coracoids process, restricted active shoulder range of shoulder joint motion and a repeated radiograph & MRI of shoulder joint showing an articulation in this area<sup>(14)</sup>.

A study on 128 Thai cadavers by Piyawingijwong S, revealed presence of Ccj in 3 cases (2.34%). In two cases it was bilateral & in one it was unilateral on left side<sup>(6)</sup>.

A case of bilateral Ccj was diagnosed by cheung TPS in a 40 year old man who was

absolutely asymptomatic; the diagnosis being made by MRI after the patient had a fall and developed left sided painful arc syndrome<sup>(29)</sup>.

Paraskevas G et al observed presence of a well-formed left sided Ccj in a dried 73 years old Caucasian male skeleton whose past medical history revealed of having diffuse shoulder pain<sup>(3)</sup>.

Anita Rani et al (2009) reported the presence of both Ccj and costoclavicular joint in their osteological studies<sup>(10)</sup>.

A thorough search of different medical and nonmedical database was undertaken by Sing VK et al. A total of 16 full text articles retrieved revealed 17 cases of Ccj. The anomalous joint was right sided in 3 cases, left sided in 4 and bilateral in 4 cases, whereas laterality was not mentioned in 6 cases. The mean age at presentation was 42 years. The male to female ratio was 1.4:1<sup>(5)</sup>.

Gibbs S et al reported a case of left shoulder pain of 5 years duration in a man of 63 yrs age in whom the cause of pain was diagnosed to be due to the presence of Ccj. Since conservative treatment gave very little relief, surgical resection of the joint was advocated<sup>(8)</sup>.

A study on 96 dried clavicles (48 pairs) of Mapuche ethnic group by Mariano del sol (2014) revealed articular facets on the conoid tubercles in 22 individual clavicles (22.9%). (12 facets (12.5%) were present on the right side; 10 (10.4%) on left side). 10 pairs of clavicles (20 clavicles) showed facets bilaterally and 2 individual clavicles presented facets unilaterally on right side. The articular facets were very prominent in 4 cases, moderately prominent in 6 cases and poorly prominent in 14 cases<sup>(30)</sup>.

**Table : A comparative study on the prevalence of coraco clavicular joint in different ethnic populations of world**

S.no	Reference	Year	Ethnic population	Study material X-rays /dry clavicle/ cadaveric dissection	No. of study material	Positive cases %	Bilateral presentatio n %	Unilateral presentation %		
								Total	Right	Left
1	Haas et al	1965	Amerstdem	Radiographs of bilateral shoulder joints of adults	1000	12 (1.2 %)	2 (16.6%)	10 (73.3%)	4 (40%)	6 (60%)
2	Kaur and jit	1991	North West India	Paired Clavicles from adult Cadavers	1000	184 (18.4%)	93 (50.54%)	91 (49.45%)	-	-
3	Nalla and Asvat	1995	South Africa	Paired Clavicles of adult Skeleton	240	23 (9.6%)	11 (47.9%)	12 (52.1%)	5 (41.6%)	7 (58.3%)
4	Cho and Kang	1998	Korea	Paired clavicles from adult Cadavers	120	10 (9.8%)	9 (90%)	1 (10%)	1 (10%)	-
5	Gumina et al	2002	Italy	Individual clavicles	1020	08 (0.8%)	-	08 (0.8%)	6 (75%)	2 (25%)
6	Piyawinjiwong et al	2006	Thailand	Dissected Individual Shoulders	128	03 (2.3%)	2 (66.6 %%)	1 (33.3%)	1 (33.3%)	-
7	Olotu et al	2008	Nigeria	Radiographs Chest of Adults	1637	09 (0.55%)	1 (11.1%)	8 (88.8%)	5 (62.5%)	3 (37.5%)
8	Sembian et al	2012	South India	Bilateral dissected shoulder joints from Cadavers	50	01 (2%)	-	01 (2%)	-	01 (2%)
9	Mariano et al	2014	Chile	Individual Clavicles	96	22 (22.9%)	-	22 (22.9%)	12 (54.5%)	10 (45.4%)
10	Nisha Kaul	2016	Delhi NCR, India	Radiographs chest adults	300	44 (14.6%)	20 (45.4%)	24 (54.5%)	12 (50%)	12 (50%)
				Individual Clavicles	150	24 (16%)	-	24 (16%)	15 (62.5%)	9 (37.5%)

“An evaluation of the prevalence of coraco clavicular joint in humans by osteological and radiological studies in Delhi and NCR region.”

**Complications:** Degenerative deformation of the coraco clavicular joint may cause cervicobrachial syndrome because of the close proximity of joint to the brachial plexus<sup>(28)</sup>. Clavicular fixation and altered shoulder mechanics due to the presence of a fully formed ccj has also been implicated as a cause of proximal humeral head fracture after a fall on an out stretched hand<sup>(3, 5)</sup>. Normally a fall on an outstretched hand is buffered somewhat by rotation of the scapula about thorax. This buffering mechanism is not possible when there is an extra articulation between coracoids process and the clavicle<sup>(2, 5)</sup>. The presence of Ccj hampers the normal movements of bones of shoulder girdle thereby decreasing limb movement which are otherwise possible to a great degree due to normal laxity of coraco clavicular ligament complex<sup>(4)</sup>. Anomalous Ccj restricts the free upward movement of the acromion and leads to a decreased space between acromion and supraspinatus<sup>(5)</sup>.

Ccj can cause supracoracoid impingement during forward flexion of arm due to reduction of space between clavicle and coracoids process (normal space being 1.3 cm)<sup>(2)</sup>.

**Conclusion:**

1. Our osteological study on clavicle shows a higher incidence of presence of Ccj amongst the population of Delhi and NCR which correlates with the observations made by Kaur & Jeet in North West Indian Population & a study in chillian population. This is in contrast to the observation made by foreign authors where the incidences found to be much lower. The studies on radiographs have also shown a higher incidence of Ccj in India (Asia) as compared to western population.
2. Our observations further emphasis the role of ethnic and genetic factors in pathogenesis of Ccj.
3. Ccj must be included amongst the first few conditions in differential diagnosis

of brachialgia's, painful arc syndrome, thoracic inlet syndrome, and restricted shoulder joint movements of unknown origin.

4. CT scan and MRI are the two important diagnostic tools for reaching at correct diagnosis of both asymptomatic and symptomatic coraco clavicular articulations.

**Bibliography:**

1. Standring S. Pectoral girdle, shoulderregion, axilla. Gray's Anatomy. The anatomical basis of clinical practice, 39<sup>th</sup> edition 2005; ch49:817-849.
2. Adnan FA. Bilateral congenital Coracoclavicularjoint. Case report and review of the literature. Act Orthopaedic Belgica 2004, vol.69 (6): 552-4.
3. Paraskevas G, Stavarakas ME, Stoltidou A Coracoclavicularjoint, anosteological study with clinical implications: a case study. Cases Journal 2009, 2:8715.
4. GuminaS, SalvatoreM, Sentis D et al. Coracoclavicularjoint: Osteologic study of 1020 human clavicles. Journal of Anatomy, Dec. 2002; 201(6):513-519.
5. Singh VK, Singh PK, Trehan R et al. Symptomatic Coracoclavicularjoint: incidence, clinical significance and available management options. Int Orthop, Dec2011; 35(12):1821-1826
6. Piyawinijwong S, Sirisathira N, Sricharoenvej S et al. Coraco clavicular joint: A Preliminary Report in Thai cadavers. Siriraj Medical Journal 2006; vol 58(no 12):1212-1215.
7. O J Lewis. The Coraco clavicular joint Journal of Anatomy, 1959; 93(Pt 3):296-303.
8. Gibbs S, Marriman JA, Sorenson E et al. Surgical Excision of a symptomatic congenital Coracoclavicularjoint. Orthopaedic Journal9/2014; 37(9): e 836-8.

“An evaluation of the prevalence of coraco clavicular joint in humans by osteological and radiological studies in Delhi and NCR region.”

9. Gradoyevitch B. CORACO-CLAVICULAR JOINT. *J Bone Joint Surg* 1939; 21:918- 920.
10. RaniA, Mishra SR, Chopra J et al. Coraco clavicular and Costoclavicular joints at a common juncture: A rare phenomenon. *Int. J. Morphol.* 2009; 27(4):1089-1992.
11. Kaur H, Jit I. Brief communication: coraco clavicular joint in northwest Indians. *Am J Phys Anthropol.*1991; 85:457-460.
12. Haramati N, Cook R.A, Raphael Bet al. Coracoclavicularjoint: normal variant in humans - A radiographic demonstration in the human and non-human primates. *Skeletal Radiography*1994; vol 23, issue 2: p 117-119.
13. Adrian S. Wright- Fitzgerald, Mark D. Balceniuk,&Anne M. Burrows. Shouldering the burdens of locomotion and posture:Glenohumeral joint structure in prosimians. *The Anatomical Records*,2010; 293:680-691.
14. Ma F Y P,Pullin C. Asymptomatic coraco clavicular joint successfully treated by surgical excision .*Science Direct*2006; vol 15, issue 5:e1-e4.
15. Cockshoot WP. The Coraco clavicular joint. *AJR.*1979; 131:313-316.
16. Sembian U, Muhil M, Nalina kumara SD. A study of coracoclavicular joint in south Indian population. *NJCA*, 2012; 1 (2):81-85. .
17. Joye O, Oladipo GS, Eroje MA et al. Incidence of coracoclavicular joint in adult Nigerian population. *Scientific Research and Eassy.*2008;vol 3(4):165-167.
18. LaneWA. The anatomy and physiology of the shoemaker. *J Anat.*1888; 22:593-628.
19. Cho BP, Kang HS. Articular facets of the coraco clavicular joints in Koreans.*ActaAnat. (Basel)* 1998; 163(1): 56-62
20. De Haas WHD, KingmaMJ, Drucker F. The coracoclavicular joint and related pathological conditions. *Ann.rheum.Dis* 1965; 24:257-266.
21. Pillay VK. The Coracoclavicularjoint.*Singapore Med J.* Sep.1967; 8(3):86-88.
22. SaundersSR.Non metric skeletal variation. *Reconstruction of life from skeleton.* A R Liss.1989; 6:95-105.
23. Nalla S, Asvat R. Incidence of coraco clavicular joint in South African population. *J Anat.* 1995; 186: 643-649.
24. Gruber WL. Die Oberschulterhakenschleimbeutel (bursaemucosae, supracoracoideae) EineMonograph emitVorbemerkungenenthaltend: BeirtageZurRegioninfraclavicularis und deltoidea.*Mem.AcDiMP. SCIS T Petersburg.*1861; 3:11.
25. Liberson F. The role of the coracoclavicular ligaments in affection of the shoulder girdle.*Am J Surg* 1939; 44: 145-157.
26. Nutter PD. Coracoclaviculararticulation.*J BoneJoint Surg* 1941; 23:177-179.
27. Wertheimer LG. Coracoclavijoint: surgical treatment of painful syndrome caused by anomalous joint.*J Bone Joint Surg* 1948; 30-A: 570-578.
28. Hall FJS. Coracoclavicular joint-A rare condition treated successfully by operation.*Br. Med.J.* 1950; 1(4656):766-768.
29. Cheung T.F.S.,BoerbomA.L.,Wolf R.F.E. A symptomatic coracoclavicular joint. *J Bone Joint Surg Br*, 2006;vol. 88-B no.11:1519-1520.
- 30.Sol del M, Vasquez B, Suazo I et al. Clavicular facet of the coracoclavicular joint: Analysis in modern skeletons of the mapuche indigenous individuals. *JASI*, 2014; VOL.63, ISSUE 1:19-23