

**MYOCARDIAL AND NEUROCOGNITIVE CHANGES IN LIGHTNING STRIKE
INJURY: A CASE REPORT**

Mustafa Ozgur¹, Kemal Gunal¹, Sevinc Duzgunoglu Boz¹, Sule Buyukkaya²

*1. Specialist, Department of Anesthesiology and Reanimation, Antakya State Hospital, Hatay,
Turkey.*

2. Department of Cardiology, Antakya State Hospital, Hatay, Turkey

Submitted on: December 2014

Accepted on: December 2014

For Correspondence

Email ID:

mustafazgr75@gmail.com

Abstract

Lightning is a frequent natural disaster, and may result in death at a rate of up to 20-30 % of affected patients. Survivors of lightning exposure can exhibit a variety of cardiac abnormalities and neurocognitive changes. In this report we present intensive care management of a case of 15 years old boy with myocardial and neurocognitive changes after lightning strike injury.

Key Words: Lightning strike, myocardial injury, neurocognitive changes

Introduction

Lightning strike is one of the frequent natural disasters and 20-30% of all lightning injuries result in death and 76% result in permanent sequelae (1). Cardiac arrest is the main cause of death and respiratory stress-related acute deaths may also be encountered (2). Various cardiac anomalies (dysrhythmias, ST-T wave alterations) have been reported in cases exposed to lightning strike, who have survived (3). Usually reversible and acute life-threatening left ventricle dysfunction or pericardial tamponade may develop due to direct exposure. Therefore, we aimed to present the myocardial and neurocognitive changes of a patient who was treated for cardiac and neurological problems due to the rarely seen lightning strike.

Case Report

A 15-year-old male patient was transferred to the emergency department of our hospital due to the lightning strike he experienced when he was in the park. It was learnt that he developed cardiac arrest at the scene and responded to cardiopulmonary resuscitation at the 20 minute. Cardioversion was applied as he developed ventricular fibrillation after his admission to the emergency room. The patient was transferred to the intensive care unit (ICU) with sinus tachycardia after he responded to cardioversion. On his first examination at the ICU, he was unconscious, the Glasgow Coma Scale was 5, and he had dilated pupils. BP was 130/90 mmHg, and the heart rate was 130 bpm (sinus tachycardia). Respiratory sounds were normal. He had second degree burns on the anterior wall of the chest, inguinal region, perianal region and the arms bilaterally. The

burn surface area was calculated as 37%. On electrocardiography, he had sinus rhythmia (104 bpm), and 1 mm ST elevation on DII, DIII and avF. The Troponin level was determined as 0.7.

Mechanical ventilation support was applied. Fluid replacement was begun after central venous catheterization and invasive central pressure monitorization. Biochemical tests were obtained every 6 hours and complete blood count was analyzed every 12 hours during the first 24 hours, together with vital sign monitorization. Urine outflow was monitored hourly and it was attempted to be kept above 50 ml. The patient was sedatized and mechanical ventilation support continued due to the history of cardiopulmonary arrest. Sedation was discontinued on day 3 of hospitalization as the vital signs were stable and his level of consciousness was evaluated. He was extubated after he was seen to be partially conscious; he responded to orders, his lung capacity was sufficient and arterial blood gases values were normal. The patient was transferred to the ward on day 7 of hospitalization and was discharged from the hospital on day 10.

Discussion

Lightning strike-related injuries are among the rare, but potentially fatal, natural disasters. Cardiopulmonary arrest is the most common cause of death. All systems are affected in a lightning strike; however, the most important and destructive effects are seen in the cardiovascular and the central nervous systems (4). Most of the patients survive despite a systole and ventricular fibrillation following the lightning strike. Other cardiac disorders include temporal conduction, rate alterations and myocardial infarction developing due to the endothelial injury in the coronary arteries. Azari et al. (5) reported a 17-year-old patient who had developed acute myocardial infarction due to lightning strike. In the literature, a case was reported, who developed a systole and ST elevation at the inferior, ST depression

on the anterior on the ECG following immediate VF (6). There are no specific ECG findings in a lightning strike, and VF, VT, SVT, AF, ST elevation, non-specific ST and T alterations may be observed on ECG (7). Cardioversion was applied once to our patient due to VF developing in the course of CPR. The ECG performed after having obtained sinus rhythm revealed ST elevation on DII, DIII and avF derivations. A prediagnosis of lightning strike-related inferior MI was made. Creatine kinase, troponin I and ECG monitorization were performed on a frequent basis for myocardial injury on the ICU follow up of our patient. However, the diagnosis of MI was disregarded due to the normal tests and ECG values. This condition was considered to be related to temporal myocardial ischemia.

Lightning strike-related neurological disorders include mental condition changes from lethargy to coma, temporal and permanent nerve injury or falls –related injuries. Mental changes and close amnesia may be seen in all lightning strikes (8). When our patient was evaluated after extubation, he was seen to respond to questions about himself and his family; however, he did not know what had happened to him and where he was. On the following days, he was partially conscious and sometimes there were hallucinations. He had a look of happiness in his face and there were meaningless laughing; therefore, he was evaluated by the psychiatrist and a diagnosis of mood alteration due to posttraumatic stress was made.

In conclusion, lightning strike is an injury which may result in high mortality and morbidity. Continuous cardiac monitorization should be applied to all patients who have cardiac or neurological anomalies, serial ECG, cardiac enzyme analysis and repeated neurological evaluation should be performed.

Acknowledgement:

Full written permission for using the photos of the case has been obtained from the patient.

References

1. Whitcomb D, Martinez JA, Daberkow D. Lightning injuries. *South Med J* 2002; 95:1331-1334
2. Murty OP, Kian CK, Husin MHA, Kumar N, Yusuf WM. Fatal lightning strikes in malaysia. *Am J Med Pathol* 2009; 30:246-251.
3. Leiria TLL, Pires LM, Kruse ML, Lima GG. Struck by lightning a case of nature-induced pre-excited atrial fibrillation. *Circ Arrhythm Electrophysiol* 2013; 6:20-21
4. Edlich RF, Farinholt HM, Winters KL, Britt LD, Long WB. 3rd. *Modern concepts of treatment and prevention of lightning injuries. J Long Term Eff Med Implants* 2005; 15:185-196
5. Azari A, Bigdelu L, Pishbin E, Rohani A. Acute myocardial infarction in a 17-year old boy secondary to lightning strike. *J Cardiothoracic Med* 2013; 1(3):104-106
6. Sağlam H, Yavuz Y, Yurumez Y, Ozkececi G, Kilit C. A case of acute myocardial infarction due to indirect lightning strike. *J Electrocardiol* 2007; 40:527-530
7. İslamoğlu Y, Çil H, Baştürk M, Tekbaş E, Elbey MA. Non-invasive electrophysiological effects of lightning strike: case series. *JAEM* 2011; 10:97-99
8. Gül M, Girişgin AS, Koçak S, Okumuş M. Lightning strike injuries. *Genel Tıp Derg* 2004; 14(1):35-38

Figure Legends

Figure 1a-1b: Appearance of the moment of lightning and the destruction on the tree.

Figure 2a-2b: General appearance of the patient on day 1 and 4 of ICU hospitalization.

Figure 3: ECG findings on admission.



Figure 1a-1b: Appearance of the moment of lightning and the destruction on the tree.

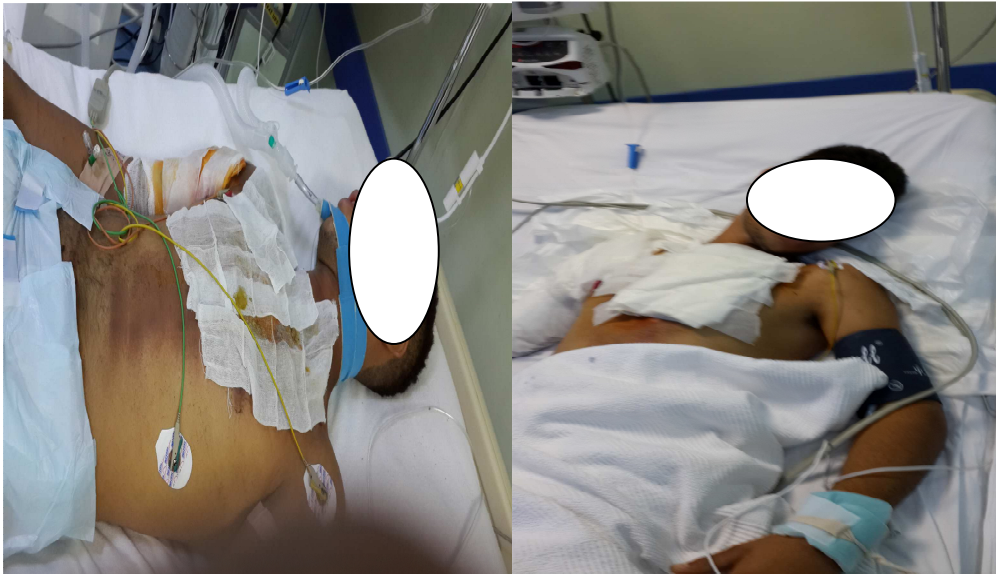

Figure 2a-2b: General appearance of the patient on day 1 and 4 of ICU hospitalization.

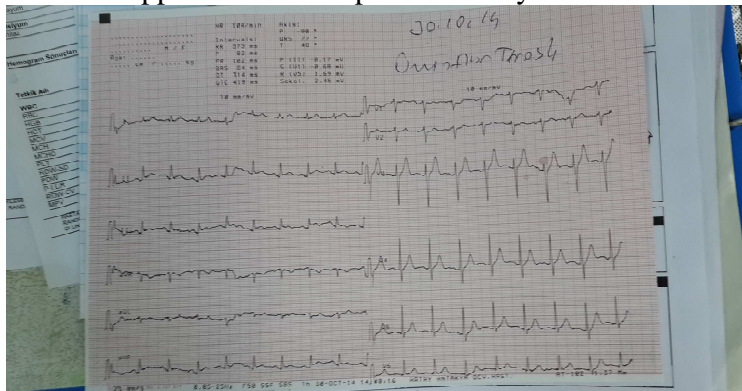


Figure 3: ECG findings on admission.