




## MEDICO RESEARCH CHRONICLES

ISSN NO. 2394-3971

DOI No. 10.26838/MEDRECH.2019.6.6.541

Contents available at: [www.medrech.com](http://www.medrech.com)

### ETIOLOGICAL STUDY OF CORNEAL LESIONS LEADING TO VISUAL IMPAIRMENT IN ADULT PATIENTS AT RURAL HOSPITAL - A DESCRIPTIVE CROSS-SECTIONAL STUDY.

**Dr. Priyanka Nangalia, Dr. Shubhangi P. Nigwekar\***

*Department of Ophthalmology, Rural Medical College, Pravara institute of medical sciences, Loni, Maharashtra, India*

| ARTICLE INFO   | ABSTRACT   | ORIGINAL RESEARCH ARTICLE |
|--|--|---------------------------|
| <p><b>Article History</b><br/> <b>Received: October 2019</b><br/> <b>Accepted: November 2019</b><br/> <b>Keywords:</b> Corneal blindness and visual impairment, infectious keratitis, ocular trauma.</p> <p><b>Corresponding author*</b><br/>           Dr. Shubhangi P. Nigwekar*</p> | <p>Corneal diseases are among the major causes of vision loss and blindness in the world today, after cataract, glaucoma, and AMD. The major causes of corneal blindness include corneal ulceration, ocular trauma, bullous keratopathy, keratomalacia, corneal degenerations and dystrophies</p> <p><b>Purpose:</b> To know the proportion of different etiologies of corneal lesions leading to visual impairment and its demographic distribution.</p> <p><b>Materials and Methods:</b> This was a hospital-based descriptive type of cross-sectional study carried out. 100 patients of &gt;20 years age with corneal lesions and with only corneal lesions having best-corrected visual acuity less than 6/18 who attended the outpatient department of Pravara Rural Hospital, Loni were included. A detailed history of all study patients and best-corrected visual acuity was recorded. Clinical diagnosis of corneal lesions was done based on slit-lamp examination of the anterior segment and posterior segment examination.</p> <p><b>Results:</b> The majority of patients were in the middle age group that is 40-60 years, out of which 56% were males and 44% were females. Most of the patients were farmers by occupation (44%). Most of the patients had very poor vision that is 43% of patients had the only perception of light vision while 37% of patients had hand movement close to face vision. Ocular trauma (44%) and Infectious keratitis (27%) were the most common causes of corneal lesions</p> <p><b>Conclusion:</b> Ocular trauma and infectious keratitis from the major causes of corneal lesions leading to visual impairment in a rural areas. Continued assessment of the burden of corneal blindness with periodic review of trends may help to effectively plan preventive, promotive and rehabilitative blindness control strategies.</p> |                           |

©2019, [www.medrech.com](http://www.medrech.com)

## INTRODUCTION

The cornea is the transparent dome-shaped surface that covers the front of the eye. The cornea contains no blood vessels to nourish it or protect it against infection. The cornea is nourished by the tear fluid and aqueous humor and must remain transparent to refract light properly. The structure of the cornea is such that even the tiniest of blood vessels can interfere with the process of vision. Thus for optimum visual acuity, the cornea must be free from any cloudy, hazy or opaque areas. The cornea copes extremely well with minor injuries or abrasions. In the event of a superficial injury, the healthy cells slide over and patch the injury before infection occurs or vision is affected. Deep injuries take a long time to heal and may result in unbearable pain, redness, visual impairment, and extreme photosensitivity. They may also cause corneal scarring or opacity, visual loss and require corneal transplantation. There are currently an estimated 15 million blind people in India and 6.8 million of these suffer from corneal blindness with vision less than 6/60 in at least one eye, and of these, about 1 million have bilateral corneal blindness. If the present trend continues, it is expected that the number of cornea blind individuals in India will increase to 10.6 million by 2020<sup>1</sup>

The major causes of corneal blindness include corneal infection, ocular trauma, bullous keratopathy, keratomalacia, corneal degenerations, and dystrophies. Corneal scarring due to infectious keratitis and ocular trauma are major causes of unilateral and bilateral corneal blindness in children and young adults. Untreated primary corneal ulceration continues to be a major cause of

global corneal blindness. This assessment of corneal blindness or visual impairment with area wise periodic review highlights its changing trends and this may help in planning preventive, promotive and rehabilitative strategies.

## MATERIALS AND METHODS

This descriptive type of cross-sectional study was conducted in the Department of Ophthalmology of Pravara rural hospital, Loni from September 2017 to August 2018. After obtaining permission from the Institutional Ethics Committee, 100 cases of corneal lesions which satisfied the inclusion and exclusion criteria were enlisted in this study

Cases with presenting complaints of diminished vision were included in this study. A detailed clinical history was recorded of each patient. Age, sex, occupation, and laterality of the affected eye were also recorded. Ocular investigations were recorded in detail. Cases diagnosed with other associated causes of blindness like cataract and retinal diseases were excluded from this study. We collected the data of visual Acuity (VA), Intraocular pressure (IOP), keratometry, pachymetry, anterior segment and posterior segment findings of the patients. If the participants had more than one ocular pathology, whether the major cause of blindness was due to a corneal cause or else, we recorded the final clinical diagnosis made by the ophthalmologist who examined those patients

An eye was considered to have corneal blindness if the best-corrected visual acuity was <6/18 due to corneal disease.

## RESULTS

Out of 100 cases of corneal lesions, we observed the following:

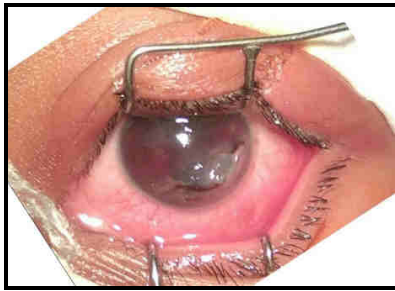
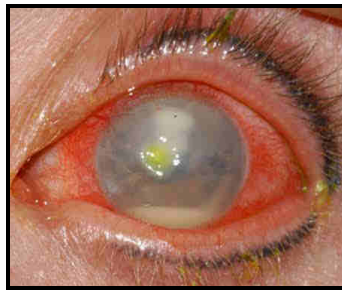
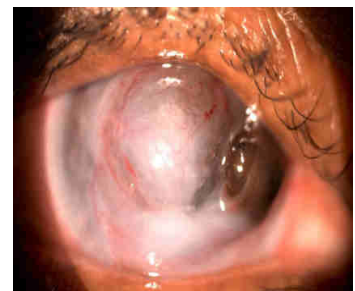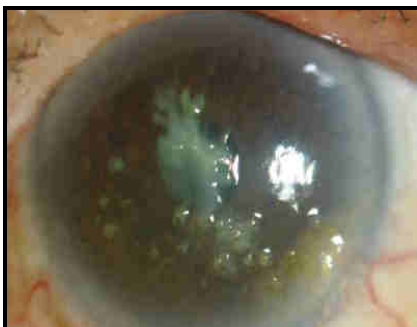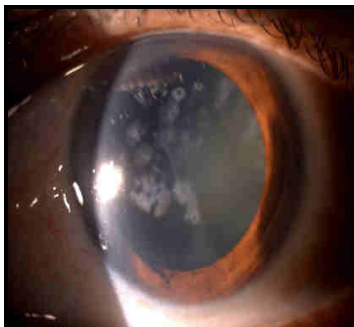
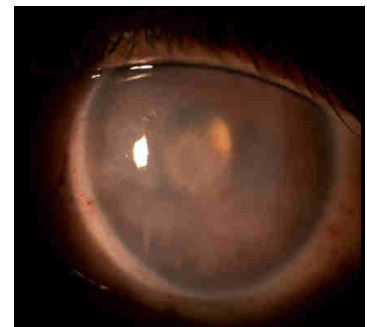
**Table No.1:** Etiological causes of corneal lesions

| Etiology  | No. | Percentage |
|---|-----|------------|
| <b>Infectious Keratitis With Preceding Trauma</b> | 34  | 34%        |
| <b>Infectious Keratitis Without Trauma</b>        | 27  | 27%        |
| <b>Corneal Degeneration</b>                       | 21  | 21%        |

|   |     |      |
|---|-----|------|
| <b>Corneal Dystrophy</b>                | 3   | 3%   |
| <b>Pseudophakic Bullous Keratopathy</b> | 5   | 5%   |
| <b>Penetrating Trauma</b>               | 10  | 10%  |
| <b>Total</b>                            | 100 | 100% |

**Table No.2:** Distribution of parameters among presenting cases in this study

| <b>Distribution of cases</b>                   | <b>No.</b> | <b>Percentage</b> |
|--|------------|-------------------|
| <b>According to sex</b>                        |            |                   |
| • Male   | 56         | 56%               |
| • Female                                       | 44         | 44%               |
| <b>According to age in years</b>               |            |                   |
| • 21-30  | 9          | 9%                |
| • 31-40  | 10         | 10%               |
| • 41-50  | 26         | 26%               |
| • 51-60  | 16         | 16%               |
| • 61-70  | 19         | 19%               |
| • 71-80  | 17         | 17%               |
| • 81-90  | 3          | 3%                |
| <b>According to the eye involved</b>           |            |                   |
| • Right eye                                    | 37         | 37%               |
| • Left eye                                     | 35         | 35%               |
| • Both eyes                                    | 28         | 28%               |
| <b>According to the occupation of patients</b> |            |                   |
| • Farmer                                       | 44         | 44%               |
| • Housewife                                    | 30         | 30%               |
| • Student                                      | 10         | 10%               |
| • Unoccupied                                   | 9          | 9%                |
| • Shopkeeper                                   | 5          | 5%                |
| • Worker                                       | 2          | 2%                |
| <b>According to visual acuity of patients</b>  |            |                   |
| <b>Perception of light</b>                     | 43         | 43                |
| <b>HMCF</b>                                    | 37         | 37                |
| <b>2/60 - FCCF</b>                             | 18         | 18                |
| <b>5/60 - 3/60</b>                             | 13         | 13                |
| <b>6/24 - 6/60</b>                             | 17         | 17                |

**Full-thickness corneal tear****Corneal ulcer with hypopyon****Perforated corneal ulcer****Spheroidal degeneration****Granular corneal dystrophy****Pseudophakic bullous keratopathy**

## DISCUSSION

The World Health Organization (WHO) estimates that corneal opacities accounted for 7% of the world's blind population in 2010, making it the 3rd most common cause of blindness.<sup>2</sup>

Although cataracts and glaucoma (in the elderly) are more common causes of visual impairment, corneal blindness affects all age groups and is a leading cause of irreversible visual impairment.<sup>3</sup>

Our study showed the most common etiology for corneal lesions as infectious keratitis (27%), Trauma (44%), corneal degeneration and dystrophy (24%) and pseudophakic bullous keratopathy (5%)

We came across early keratoconus (1%) but none of the cases showed features of corneal hydrops. Only visual impairment was seen due to irregular astigmatism in keratoconus

Similar findings were reported in a study done in the South Indian population

where corneal blindness was predominantly due to ulcerative keratitis (59.5%) and trauma (23.2%).<sup>4</sup>

Also, a study was done in Nagpur (in Maharashtra State) showed that infective keratitis was the leading cause of blindness, and the other etiologies being corneal dystrophies, degenerations and corneal injuries in adults.<sup>5</sup>

The similar results were found in rural areas of Northern China by Wang et al. where ulcerative keratitis (40.0%) was the commonest cause of corneal blindness followed by ocular trauma (33.3%).<sup>6</sup>

Ulcerative keratitis (35.6%), surgical bullous keratopathy (27.8%), and trauma were found to be the most common causes of corneal blindness and visual impairment in Thailand.<sup>7</sup>

Dandona et al conducted a study in southern Indian and found that corneal blindness was due to keratitis (22.2%), trauma (23.2%), iatrogenic (5.0%), spheroidal

degeneration (4%), traditional eye medicine (4.0%).<sup>4</sup>

Tandon et al conducted a hospital-based study in New Delhi in 2010 and showed 59 diagnosed cases of corneal blindness with distribution of corneal infection (62.5%), Chemical injury (5.7%), corneal dystrophy (7.1%), keratomalacia (5.4%), bullous keratopathy (8.9%), and corneal degeneration (3.6%).<sup>8,9</sup>

Most studies from the United States in 1996-2000 have shown pseudophakic bullous keratopathy to be the leading indication for keratoplasty (18.9%–40.9%).<sup>10</sup> In a study involving 2022 penetrating keratoplasties performed in a tertiary eye care center in North India, performed during the period from June 1997 to November 2003, bullous keratopathy accounted for 13.5% of all operated cases.<sup>11</sup> In cataract-related corneal edema, aphakic bullous keratopathy (7.27%) was almost as frequent as pseudophakic bullous keratopathy (6.18%). Visual rehabilitation after keratoplasty is compromised in these cases due to a high incidence of graft failure contributed by increased intraocular pressure.<sup>12</sup>

However, in our study, we could find only 5% of cases of pseudophakic bullous keratopathy. Similarly, Dandona et al found 5% of cases of PBK in their study. In earlier times, the incidence of pseudophakic bullous keratopathy was higher as it was the era of IOL implantation and it was a relatively new technique. But now due to newer microsurgical techniques, newer IOLs, the use of viscoelastic and improved training programs for surgeons has improved the surgical outcome and reduced the incidence of bullous keratopathy. This explains the changing trend of the occurrence of PBK as a reason for visual impairment.

India has become free from Trachoma—a chronic infective disease of the eye and a leading cause of infective blindness—with an overall prevalence found to be only 0.7% in the National Trachoma Survey Report (2014-17)

In our study, not a single case of trachoma was found. It could be due to the geographical factors as well as the success of trachoma implementation programs. This shows the changing trend of etiological distribution pattern due to corneal blindness.

Moshirfar et al<sup>13</sup> claimed that 1 in 2000 patients (0.05%) developed ectasia after femtosecond assisted LASIK. In the case of microkeratome assisted LASIK. A study by Spadea et al<sup>14</sup> estimated that 0.1% of patients with preoperative zero to low ectasia risk will go on to develop ectasia after microkeratome assisted LASIK.

The incidence of ectasia was 0.033% over 8 years in a study conducted following LASIK between August 2007 and August 2015 which was performed at the Specialty Eye Hospital Svjetlost Zagreb and associated centers in Split, Sarajevo, and Banja Luka<sup>15</sup>

No such cases were reported in our study as refractive surgery is not commonly performed in our rural area as against other urban areas.

## CONCLUSION

Assessment of the distribution pattern of corneal lesions leading to visual impairment is important to know the changing trends and will help in planning preventive, promotive and rehabilitative blindness control strategies.

## Limitations

- The sample size and study period were limited.
- This study was hospital-based and not community-based.

## BIBLIOGRAPHY

1. Vemparala R, Gupta P. National Programme for Control of Blindness (NPCB) in the 12th Five-year plan: An Overview. Delhi J Ophthalmol 2017;27;290-2.
2. Pascolini D, Mariotti SP. Global estimates of visual impairment: 2010. Br J Ophthalmol 2012; 96: 614–8.
3. Solomon A. State of the World's Sight. Vision 2020: the Right to Sight 1999–2005.

- Geneva: World Health Organization, WHO Press, 2005.
4. Dandona R, Dandona L. Corneal blindness in a southern Indian population: Need for health promotion strategies. *Br J Ophthalmol* 2003;87:133-41
  5. Nikose A. A study of frequency and etiopathogenesis of corneal blindness at the tertiary health care center. *Panacea Journal of Medical Sciences*, May-August 2015;5(2);88-91
  6. Wang H, Zhang Y, Li Z, Wang T, Prevalence and causes of corneal blindness. *Clin Experiment Ophthalmol*, 2014 Apr, 42(3):249-53
  7. Prabhasawat. Causes of Corneal Blindness: A Multi-Center Retrospective Review. *J Med Assoc Thai* 2007; 90 (12): 2651-7
  8. Prevalence of corneal disease in rural Indian population; Noopur Gupta, Praveen Vashist, Radhika Tandon. *BJO* 99(2). Nov 2014 001:10. 1136/bjo *Ophthalmol* 2014-305945
  9. Gupta N, Vashist P, Tandon R, et al. *Br J Ophthalmol* 2015;99:147-152.
  10. Cosar CB, Sridhar MS, Cohen EJ, et al. Indications for penetrating keratoplasty and associated procedures, 1996-2000. *Cornea*. 2002;21:148-151.
  11. Sony P, Sharma N, Sen S, Vajpayee RB. Indications of penetrating keratoplasty in Northern India. *Cornea* 2005;24:989-91.
  12. Dandona L, Naduvilath TJ, Janarthanan M, Rao GN. Causes of corneal graft failure in India. *Indian J Ophthalmol* 1998;46:149-52.
  13. Moshirfar M, Smedley JG, Muthappan V, Jarsted A, Ostler EM. Rate of ectasia and incidence of irregular topography in patients with unidentified preoperative risk factors undergoing femtosecond laser-assisted LASIK. *Clin Ophthalmol*. 2014;8:35-42. doi:10.2147/OPHTH.S53370.
  14. Spadea L, Cantera E, Cortes M, Conocchia NE, Stewart CW. Corneal ectasia after myopic laser in situ keratomileusis: a long term study. *Clin Ophthalmol*. 2012;6:1801-1813. doi:10.2147/OPHTH.S37249.
  15. Maja Bohac, Mateja Koncarevic, Adi Pasalic, Alma Biscevic, Maja Merlak, Nikica Gabric & Sudi Patel (2018): Incidence and Clinical Characteristics of Post LASIK Ectasia: A Review of over 30,000 LASIK Cases, *Seminars in Ophthalmology*, DOI: 10.1080/08820538.2018.1539183
-