



## ENDODONTIC MANAGEMENT OF MAXILLARY CANINE WITH TWO ROOT CANALS: A CASE REPORT

**Dr. Siddhi Shetye<sup>1</sup>, Dr. Mitali Bhosale<sup>1\*</sup>, Dr. Hemant Vagarali<sup>2</sup>**

1. Conservative dentistry and Endodontics, Consultant, Porvorim- Goa

2. Associate Professor, Department of Conservative Dentistry and Endodontics, Maratha Mandal's Nathajirao G. Halgekar Institute of Dental Sciences & Research Centre, Belgaum.

### ARTICLE INFO

### ABSTRACT

### CASE REPORT

#### Article History

**Received: May 2020**

**Accepted: June 2020**

**Keywords:** Canine, Two Root Canals, CBCT, Aberrant anatomy

**Corresponding author\***

**Dr. Mitali Bhosale**

For a successful outcome of surgical or non-surgical root canal treatment an in-depth knowledge of the root canal anatomy is a must. Understanding the root canal is an essential part of root canal treatment. This article aimed to present a case of endodontic management of maxillary canine with two root canals in a single root. Cone Beam Computed Tomography (CBCT) was further used to confirm their presence. This article highlights the importance of a thorough knowledge of the root canal anatomy and their aberrations, emphasizing on the use of advanced diagnostic techniques to further aid towards the success of the root canal treatment.

©2020, [www.medrech.com](http://www.medrech.com)

## INTRODUCTION

A successful root canal treatment is achieved through proper mechanical and chemical cleansing followed by complete obturation to prevent the ingress of microbes [1]. The clinician must possess a thorough knowledge of the root canal anatomy and should be able to identify those teeth which vary from the norm [2]. Anatomical variations in the root canal anatomy pose a challenge to the success of endodontic treatment [3]. Aberrations or anatomical variations such as extra roots when evident on pre-operative radiographs are easier to treat. In comparison, when similar abnormalities are not noticed, compromising the treatment prognosis [4]. These additional root canals can later be discovered either by the chance of entry of a

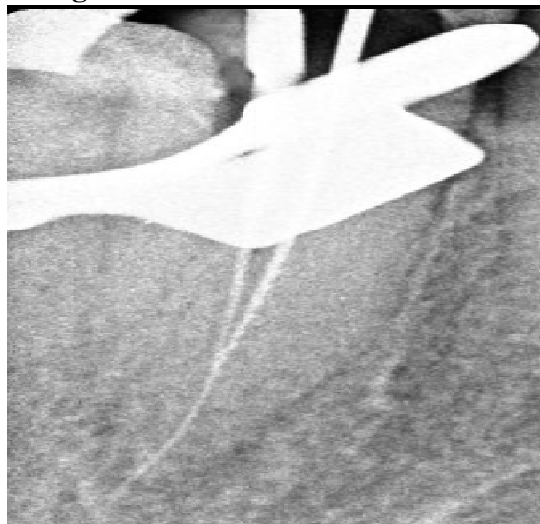
working endodontics file or using advanced diagnostic technology such as microscopes, CBCT imaging, etc. Root canal Morphology has been extensively researched, as there exist tremendous variations in the root canal anatomy which makes each endodontic case unique [5]. Literature about the maxillary canine shows it to be a predominantly single-rooted tooth with a single canal, deviations from this being rare. The following case is a report of endodontic treatment of a maxillary canine with 2 root canals. The extra canal was a chance discovery while negotiating and widening the existing root canal. The finding was later confirmed using radiographs and CBCT.

## CASE REPORT

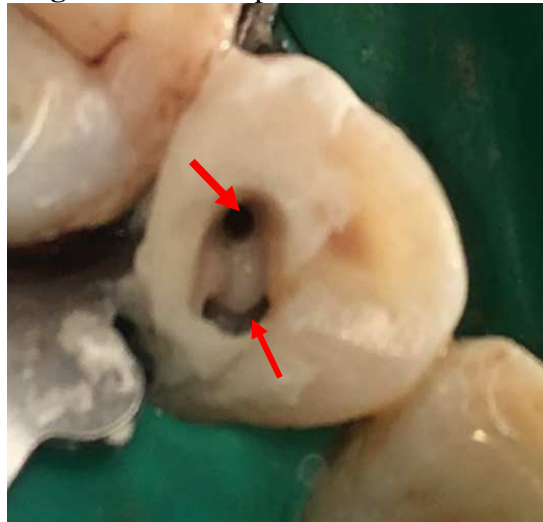A 30-year-old male reported to the clinic with pain in the maxillary left the canine region. The patient gave a history of pain which was dull and intermittent relieved of taking medication. Clinically a deep carious lesion was present on the Disto-buccal aspect. Vitality testing was done using electric pulp tester which suggested that the tooth was non-vital. Informed consent was taken from the patient and Local anesthesia (Indoco remedies Ltd., Promoted by Warren pharmaceuticals,

Goa, India) was administered. The tooth was isolated using a 6x6" rubber dam (Hygienic, Coltene Whaledent). Access opening was performed using a round bur (Mani Inc, Japan) in a high-speed rotor. The Root canal was then negotiated with a no. 10 K-file and a working length of 25 mm were established. During instrumentation, the No. 10 K-file appeared to enter another orifice located palatally. On assessment, a No. 8 K-file, extended up to the entire working length (Figure 1 & 2).

**Figure 1:** Assessment of root canals



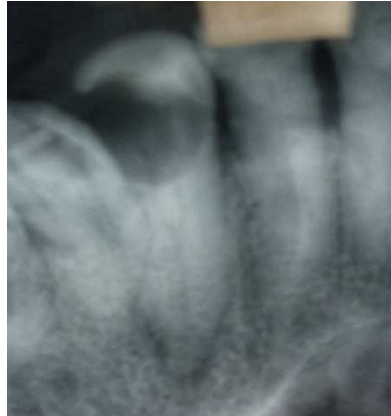**Figure 2:** Two separate orifices located



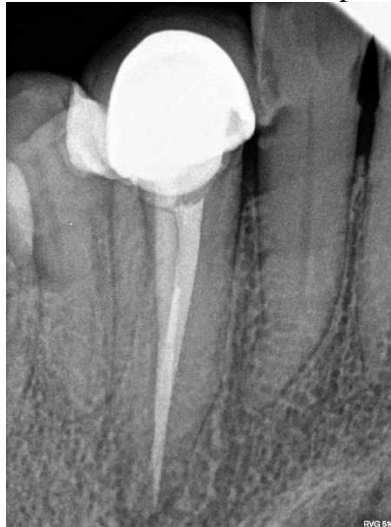On careful radiographic examination (Figure 3 & 4), A Vertuccitype VI canal configuration

was seen wherein two separate canals with two distinct apices were identified.

**Figure 3:** Radiograph showing a Vertucci type VI canal configuration



**Figure 4:** Two distinct root canal apices are seen



Both the canals were instrumented using ProTaper Next Rotary system up to X2 file (Dentsply Maillefer, Ballaigues, Switzerland). Copious Irrigation was performed in between instruments using normal Saline and 3% NaOCl (Vensons, India). After a final rinse with 17% EDTA the canals were obturated using lateral condensation technique with Gutta Percha (Dentsply Maillefer, Ballaigues, Switzerland) and AH Plus sealer (Dentsply, Konstanz, Germany).

The access cavity was restored using composite. The patient was later referred for a multiple Sliced CBCT scan which revealed 2 distinct canals with separate apices. The patient was kept on a six month follow up and evaluated radiographically; the tooth was asymptomatic ever since.

## DISCUSSION

This case report gives an insight regarding a fixed number of teeth is uncertain [6]. It is the responsibility of the dental surgeon to identify these hidden canals. To have a predictable outcome of the endodontic treatment, these extra canals can be identified using different diagnostic methods such as Dental loupes, Endodontic microscopes, Trans-illumination of the pulp chamber, CBCT, ophthalmic dyes, etc. [7]. In the absence of such advanced equipment, the clinician can take radiographs at various angulations. Other than the above-mentioned approaches, various intraoperative methods can be implemented such as modification of the access cavity for improved visualization, careful observation of the dentinal map,

uncovering calcification, champagne/bubble test using warm NaOCl [8, 9].

Finding more than one canal in a maxillary canine is quite rare. Very few cases of maxillary canine with two separate canals have been documented in the literature. Diagnosis of a second root canal is difficult in cases where the roots are superimposed on each other. Hence the use of advanced imaging technologies such as CBCT helps give a clear picture of the canal anatomy. In this case, 2 canals with distinct apices were seen.

### CONCLUSION

This case report brings to light that radiographic evaluation should not be the only diagnostic method employed. It should always be supplemented with other pre-operative and intra-operative methods mentioned earlier.

**CONFLICTS OF INTEREST:** None

### REFERENCES

1. Cohen AS, Brown DC. Orofacial dental pain emergencies: endodontic diagnosis and management. In: Cohen S, Burns RC editors. *Pathways of the pulp*. 8<sup>th</sup> edition Boston, MA, USA: Mosby 31-75
2. Nallapati S. Three canal mandibular first and second premolars: a treatment approach. *J Endod*. 2005;31(6):474-476. doi:[10.1097/01.don.0000157986.69173.a6](https://doi.org/10.1097/01.don.0000157986.69173.a6)
3. Vertucci FJ. Root canal anatomy of the human permanent teeth. *Oral Surg Oral Med Oral Pathol*. 1984;58(5):589-599. doi:[10.1016/0030-4220\(84\)90085-9](https://doi.org/10.1016/0030-4220(84)90085-9)
4. Pineda F, Kuttler Y. Mesiodistal and buccolingual roentgenographic investigation of 7,275 root canals. *Oral Surg Oral Med Oral Pathol*. 1972;33(1):101-110. doi:[10.1016/0030-4220\(72\)90214-9](https://doi.org/10.1016/0030-4220(72)90214-9)
5. Caliskan MK, Pehlivan Y, Sepetcioğlu F, Türkün M, Tuncer SS. Root canal morphology of human permanent teeth in a Turkish population. *J Endod*. 1995;21:200e204. [https://doi.org/10.1016/S0099-2399\(06\)80566-2](https://doi.org/10.1016/S0099-2399(06)80566-2)
6. Alapati Subbarayudu, Zaatar Essam I, Shyama Maddi, Al-Zuhair Nohoud. Maxillary canine with two root canals. *Med Princ Pract*. 2006;15:74e76.
7. Karunakaran JV, Shobana R, Kumar M, Kumar S, Mankar S. Management of middle mesial canal in mandibular second molar. *J Pharm Bioallied Sci*. 2012; 4(Suppl 2):S161-S164. doi:[10.4103/0975-7406.100259](https://doi.org/10.4103/0975-7406.100259)
8. Bhargavi N, Velmurugan N, Kandaswamy D. The hunt for elusive canals. *Endodontology*. 2005;17(1):18-21.
9. Chawla A, Sujana A, Chawla HS. Endodontic management of maxillary canine with two root canals. *Indian Journal of Dentistry*. 2014 Aug 1; 5:112-5.