




## MEDICO RESEARCH CHRONICLES

ISSN NO. 2394-3971

DOI No. 10.26838/MEDRECH.2021.8.2.496

Contents available at [www.medrech.com](http://www.medrech.com)

### SYNCHRONOUS PRESENTATION OF TWO DENTIGEROUS CYSTS AND AMELOBLASTOMA: EIGHT-YEARS FOLLOW-UP.

Juárez-Rebollar Alejandra Giselle<sup>1\*</sup>, Cortés-Hernández Sergio<sup>2</sup>, Juárez-Rebollar Daniel<sup>3</sup>, Juárez-Paredes Celso Marcelo<sup>4</sup>

1. Maxillofacial Surgery, National Medical Center "Siglo XXI", Mexico

2. Maxillofacial Surgery, National Medical Center "La Raza", Mexico

3. Neurosurgery, Regional Hospital Lic. Adolfo López Mateos, Mexico

4. Gerontology, Mexican Institute of Social Security (IMSS), Mexico

#### ARTICLE INFO

#### ORIGINAL RESEARCH ARTICLE

##### Article History

Received: March 2021

Accepted: April 2021

Keywords: dentigerous cyst, cyst, ameloblastoma, enucleation, odontogenic cyst

##### Corresponding author\*

Dr. A. G. Juárez-Rebollar

Dentigerous cysts are benign lesions mainly related to the crown of a tooth, early diagnosis is essential (which is almost always done radiographically and sometimes clinically) these not usually causing symptoms unless these are large and generate compression on nerve structures, the possibility of transformation or the evolution of these lesions to ameloblastomas has been described in the literature, possibly due to cellular and protein changes, among others, which are still under study. Ameloblastomas, on the other hand, are aggressive benign tumors and their possible formation from a dentigerous cyst has been described. It is important to have a good histopathological diagnosis since sometimes similarities can be observed and these can generate controversy or confusion between them. The present clinical case is representative because it involves both lesions in the same site, the importance lies in the fact that conservative treatment was provided through enucleation and curettage of the lesions performed at the Maxillofacial Surgery at "La Raza" National Medical Center. And then the patient was kept under control, showing clinical and radiographic results at eight years of follow-up, without recurrences, with adequate evolution and a good prognosis.

©2021, [www.medrech.com](http://www.medrech.com)

#### INTRODUCTION:

There are different odontogenic lesions, within these lesions cysts and tumors are distinguished. One of the main odontogenic cysts is the Dentigerous Cyst, which derives from the reduced epithelium of the enamel and has been described as a cavity lined with epithelium that is usually located

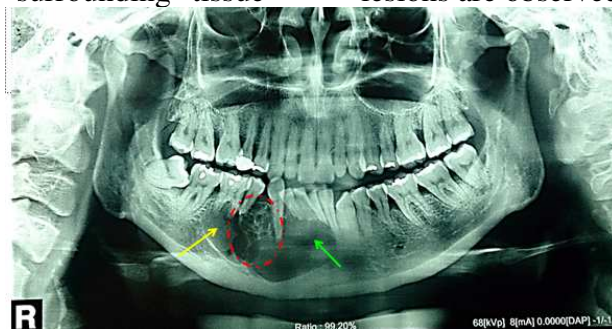
around or concerning the crown of a developing tooth, either included or not erupted.<sup>1,2,3</sup> It is usually characterized by presenting an asymptomatic increase in volume, although when it grows it can cause compression of nerve structures and present pain; usually found as a radiographic finding and shows on radiography as a unilocular

radiolucent lesion associated with a retained or embedded tooth<sup>4</sup> Treatment is usually by enucleation and extraction of the involved tooth.<sup>1</sup> It is mentioned in some studies that dentigerous cysts are usually small (<2.0 or unilocular) but when these lesions are larger or were not detected early, the lesion can grow, even present in multilocular shape; which generates a possible confusion, and reported as larger lesions but with more aggressive behavior, such as ameloblastomas.<sup>5,6</sup> On the other hand, ameloblastomas are benign, slow-growing lesion<sup>7</sup>, these are formed from the odontogenic epithelium (Serres and Malassez remains) or even from the epithelial wall of odontogenic cysts, such as Dentigerous Cyst<sup>8,9,10</sup>. The exact reason for its aggressiveness is unknown<sup>7</sup> and the reason why neoplastic changes occur, although there are studies that mention it is because of tumor necrosis factor, interface proteins, and antiapoptotic proteins, it represents 3-19% of odontogenic tumors, treatment can be enucleation or resection, depending on the type of lesion and histological variations.<sup>11</sup> One of the reasons for which there may be confusion in the diagnosis of these lesions is the coexistence of some characteristics (mainly imaging) between both lesions, “of the dentigerous cyst and the Ameloblastoma”; For example, it is well known that cysts generally present an expansion (it is generally observed unilocular) and is usually associated with the crown of a tooth, for its part, Ameloblastoma usually presents thinning of the cortical including in some cases there is the destruction of them, extension into surrounding tissue

causing the appearance of increased volume.<sup>12</sup> The region in which both lesions are most common is at the jaw, the diagnosis depends largely on the histopathological evaluation and it is in this part where there can be controversy and confusion, according to Ackermann<sup>13</sup>, Philipsen<sup>14</sup>, Robinson<sup>15</sup>, they mention that histologically the degeneration of solid/multicystic ameloblastomas (SMA) should be considered since it is usually extensive and sometimes gives the appearance of a cyst identical to the Dentigerous Cyst; Likewise, it has been studied that the presence of a unicystic Ameloblastoma (UA) lacks a mural or intraluminal component (mainly the luminal or simple variant) and this variant of Ameloblastoma can also give a misinterpretation and considered a simple cyst.<sup>13-16</sup> For all the above, a representative case of both pathological entities is presented, treated in the Maxillofacial Surgery service of “La Raza” Medical Center.

#### CASE REPORT:

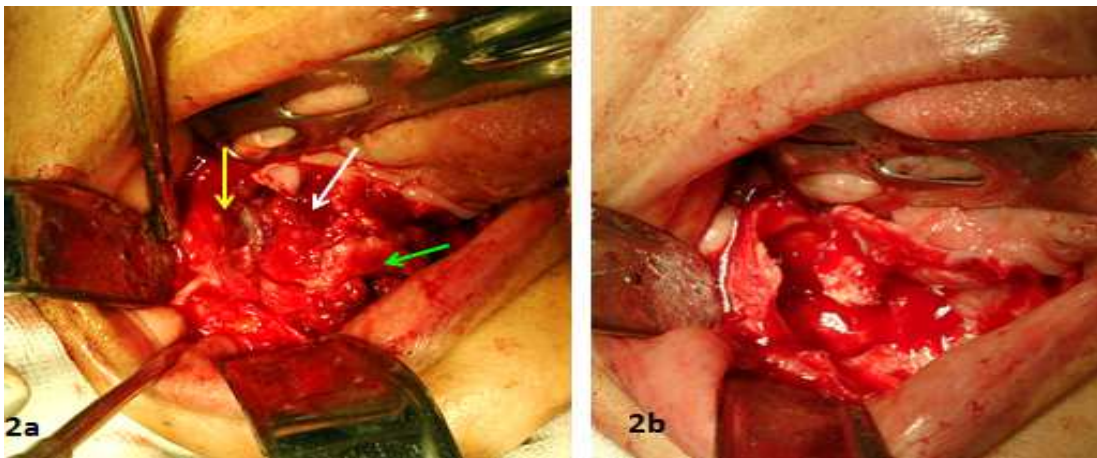
A 39-year-old woman with no significant pathological history, who had a surgical history of enucleation of a dentigerous cyst (performed by her dentist), approximately 8 years ago (in 2013). Later, she had follow-up appointments for a year, and radiographs were performed periodically, however, suddenly she begins with mandibular paresthesias on the right side, for which she is evaluated in our Maxillofacial Surgery service, for which an orthopantomography is performed to complement the clinical diagnosis, in this radiograph two images suggestive of two jaw lesions are observed (*image 1*).



**Image 1.** Panoramic view of a 39-year-old woman, who presents Lesion 1 (yellow arrow), lesion 2 (green arrow), and lesion 3 (red circle) in the right jaw, showing dental displacement of the inner incisors, the second premolar is absent due to prior procedure.

Clinically, she did not present an increase in extra oral volume or facial asymmetry, intraorally she presented an expansion of the oral cortical at the level of the canine and lower the first premolar, she did not present tooth mobility, other normal structures. An incisional biopsy was performed in which the diagnosis of the dentigerous cyst was reported, so it was scheduled for enucleation and curettage of the lesion in the operating room under balanced general anesthesia. A Semi-Newman flap was made exposing the lesions

of the right mandible (*image 2a*), each one surrounded by a well-defined firm capsule, the extension of these lesions was from the left lateral incisor to the lower right second molar, yellow in color, with a yellow surface smooth, the lesions were removed, then the enucleation and curettage were performed without complications, it was also decided to extract all the involved teeth, the surgical bed was irrigated with physiological solution, then it was sutured, hemostasis was verified in the operating room (*image 2b*),.

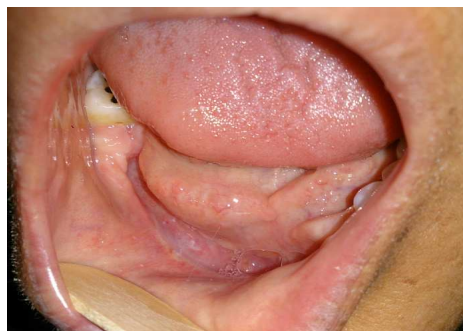

**Image 2a** Semi-Newman flap in the right jaw, the lesions (yellow, white, and green arrows) are observed before enucleating them, and the alveoli of the teeth that are extracted are observed.

**Image 2b.** The surgical site is appreciated without injuries or teeth involved.

the sample was sent to pathology for pathological study and the procedure was completed without complications. The histopathological result diagnosed the presence of two dentigerous cysts and multicystic ameloblastoma. The patient was

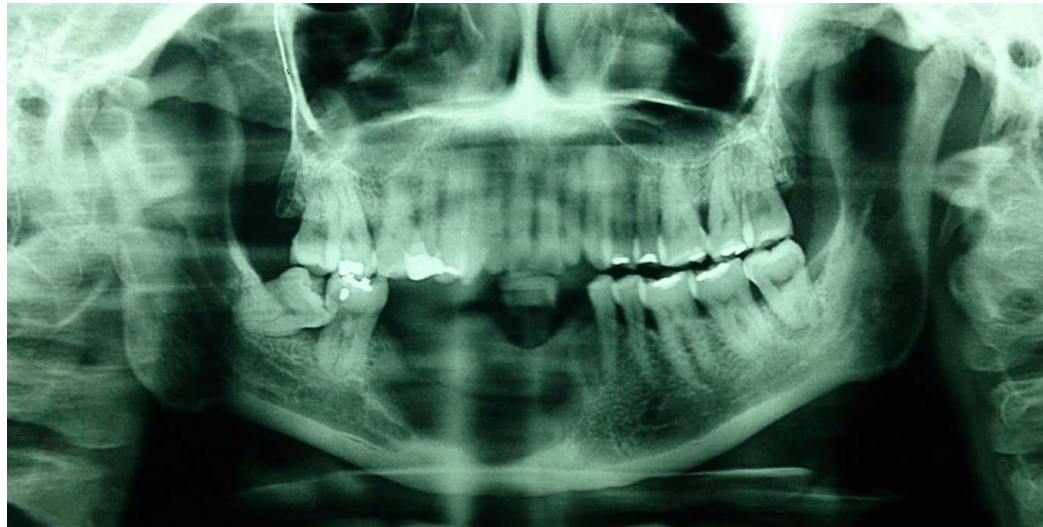
evaluated at 7 days postoperatively, who had adequate evolution and remained in the healing process, later she was evaluated at two weeks, one month, three months and six months and one year without showing recurrence of the lesion (*image 3*)



**Image 3.** Intraoral photograph one year after enucleation and curettage, the surgical bed (of the three lesions) is observed with adequate evolution and healing, without recurrence.

is currently under radiographic control and annual clinical evaluations. **Image 4** shows an

8-years control radiographs with no data of recurrence of any of the lesions.



**Image 4.** Panoramic X-ray, control at 8 years of enucleation and curettage of two dentigerous cysts and one ameloblastoma, where the entire mandibular border is appreciated, with no data of recurrence or the presence of any lesion.

#### DISCUSSION:

The main and coincident characteristics between cystic lesions (in this case the Dentigerous cyst) and Ameloblastoma must be taken into account, despite classified as benign, these may have similarities and cause confusion in the diagnosis, it is important to consider that the histopathological study will always give the definitive diagnosis. In the case presented, the patient had a history of having presented a dentigerous cyst that was previously enucleated, but another larger lesion appeared with a radiographic appearance of being two lesions, however when performing the surgical procedure, we noticed the presence of 3 lesions. Which were reported as two dentigerous cysts and a multicystic Ameloblastoma. The appearance of these entities together is very rare, a revision of the lamellae was requested, finding said lesions. Some authors like Goss, Ojo, and Akpata<sup>17,18</sup> they mention that the most effective treatment in patients is enucleation or cystectomies to remove all the pathological tissue, as was done

in this case, although there are also other cases and studies where surgeons opted for resection, mainly due to the suspicion of ameloblastoma<sup>7,19</sup>. It has been described in other studies, in which the histological characteristics of odontogenic cysts are mentioned, for example, that these are composed of a wall of non-keratinized stratified squamous epithelium, which can present keratinization as a consequence of metaplasia so that in the epithelium of lining may present multiple hair cells and inflammatory infiltrate in the connective tissue, including epithelial remains can be found in the lumen of the cyst; It is also mentioned that dentigerous cysts can have a neoplastic proliferation and these may transform into Ameloblastomas, in turn, there are also reported cases with dyskeratotic transformation and the development of squamous cell carcinoma.<sup>20</sup> Another difficulty in the diagnosis of both lesions is that these do not usually present specific or intense symptomatology, both are usually found as a radiographic finding, in the case presented the

patient presented a slight increase in volume in the anterior region and right mandibular premolar accompanied by paresthesia in the same region. Both lesions (dentigerous cyst and Ameloblastoma) have been reported more frequently in the jaw and molar region.<sup>21,22,23</sup>

#### CONCLUSIONS:

The importance of making an early diagnosis with consultation studies (mainly radiographic, tomography, etc.), in addition to an incisional biopsy of the lesion or lesions, will help to decide the best treatment according to the case and the histologically reported pathology, the possible variations or similarities between one lesion and another make the need to keep patients under control relevant, since there may be unusual presentations as in the case of this article, possible recurrence, possible transformation into other lesions at the expense of the histological changes that may occur, another important point is to assess the size of the lesion and the proximity to other anatomical structures. As well as, consider the viability of the teeth involved in the injury to determine if there is the possibility that any of them remain or it will be necessary to extract all the teeth involved, including those adjacent or immediate to the injury (which are in intimate contact). Although it should be noted that it does not occur in all cases. The important thing is the clinical-radiographic evaluation and the final pathological diagnosis.

#### FUNDING:

We appreciate the support provided by the Editorial Committee and editor-in-chief, for their understanding and help in presenting this research study. We have not received financing nor do we have sponsors to carry out this study.

#### COMPETING INTEREST STATEMENT:

The authors have declared no competing interest. The study has not been funded by any institution. We confirm all relevant ethical guidelines have been followed.

#### REFERENCES

1. Tovío E., Anaya L, Rivera D. ¿Dentigerous cyst or ameloblastoma? Importance of histological analysis in the diagnosis of these pathologies. *Rev Cient Odontol (Lima)*. 2020; 8 (3): e034 DOI: 10.21142 / 2523-2754-0803-2020-034
2. Peralta E, Peña C, Rueda A. Diagnosis of dentigerous cyst in follicular sacs of third molars included. *Acta Odont Col*. 2020; 10 (1): 24-36. DOI: <https://doi.org/10.15446/aoc.v10n1.82315>
3. Öney Ö, Süslü A, Yılmaz T. Huge dentigerous cysts in the maxillary sinus: a rare case in childhood. *Turk Arch Otorhinolaryngol*. 2019; 57 (1): 54-6. DOI: 10.5152 / tao.2019.1920
4. Floriam L, Danelon M, Oliveira V, Gonçalves N, Báez L, Macchetti D. Dentigerous cyst in dentistry: case report. *Journal of Latin American Pediatric Dentistry* 2019, 9: (2) 160-170
5. Bhayya D, Shyagali T. Dentigerous cysts of inflammatory origin. A case report. *The Internet Journal of Dental Science* 2009; 7 (2): 51-6.
6. Saenz L., Palacios E., Castro Y., Pineda M., Surgical approach of the dentigerous cyst. *Odontol. Sanmarquina* 2014; 17(2): 94-96
7. Mendenhall W., Werning J., Fernandes R., Malyapa R., Mendenhall N. Ameloblastoma. *Am J. Clin Oncol*. 2007 Dec; 30 (6): 645-8.
8. Masthan K., Anitha N., Krupaa J., Manikkam S. Ameloblastoma. *J. Pharm Bioallied Sci*. 2015; 7 (Suppl 1): S167-S170.
9. Barnes L., Eveson J., Reichart H., Sidransky D. (Eds): WHO Classification of Tumor. Pathology and Genetics of Head and neck Tumors. Lyon: IARC Press; 2005.

10. Regezi J., Sciubba J., Jordan R. Oral Pathology: Clinical Pathologic Correlations. 6 ed. St Louis Missouri: Elsevier; 2012
11. Reichart P., Philipsen H., Sonner S. Ameloblastoma: biological profile of 3677 cases. Eur J. Cancer B Oral Oncol. 1995 Mar; 31B (2): 86-99
12. Ceylan Z., Barton F. Branstetter I, Simion I. Chiosea, Leon E. Ameloblastoma and Dentigerous Cyst Associated with Impacted Mandibular Third Molar Tooth. Radiographic 2010 1415-1420
13. Ackermann G., Altini M, Shear M. The unicystic ameloblastoma: a clinic-pathological study of 57 cases. J Oral Pathol. 1988; 17:541-546.
14. Philipsen H., Reichart P. Unicystic ameloblastoma: a review of 193 cases from the literature. Oral Oncol. 1998; 34:317-325.
15. Robinson L, Martinez M. Unicystic ameloblastoma: a prognostically distinct entity. Cancer. 1977;40: 2278-2285.
16. Barrett A., Sneddon K., Tighe J., Gulati A., Newman L., Collyer J., et. al. Dentigerous Cyst and Ameloblastoma of the Jaws: Correlating the Histopathological and Clinico-radiological Features Avoids a Diagnostic Pitfall. International Journal of Surgical Pathology 2017, 25(2) 141–147. DOI: 10.1177/1066896916666319
17. Goss A. Dentigerous cyst: an excellent prognostication. Oral Surg 1983;56(1):110
18. Ojo M, Akpata O. Case report of dentigerous cyst of lower incisor. Afr Dent J. 1992; 6:34-37
19. Urbano S, Tovío E, López E. Rapidly growing multicystic ameloblastoma with partial reconstruction. Rev Cubana Estomatol. 2018; 55 (4): 1-8.
20. Tovío E., Anaya L., Rivera D. Dentigerous cyst or ameloblastoma? Importance of the histological analysis in the diagnosis of these pathologies. Rev Cient Odontol (Lima). 2020; 8(3): e034 DOI: 10.21142/2523-2754-0803-2020-034
22. Bertolo N, Giroto D, Jeremías F, Aparecida EM, Aguiar C. Diagnosis and conservative treatment of dentigerous cyst: 3-year follow-up. Rev CES Odont. 2018; 31 (1): 57-65. doi: <https://doi.org/10.21615/4777>
23. Estrada M, Rodríguez E, Lenés A, Toledo B. Mandibular ameloblastoma. Analysis of 8 cases. Rev Multimed. 2018; 22 (4): 871-82.
24. Kirtaniya B., Sachdev V, Singla A, Sharma AK. Marsupialization: a conservative approach for treating dentigerous cyst in children in the mixed dentition. J Indian Soc Pedod Prev Dent 2010; 28: 203-208.