

**COW HORN INJURY CAUSING SCLERA RUPTURE WITH SUBCONJUCTIVAL
DISLOCATION OF CATARACTOUS LENS**

**Rajendra P Maurya, Dr. Prakash Kumar, Dr. Ishan Yadav, Dr. Prashant Bhushan,
Dr. Virendra P. Singh, Dr. Mahendra K. Singh**

*Department of Ophthalmology, Institute of Medical Sciences, Banaras Hindu University
Varanasi-221005 UP, India*

Submitted on: January 2015
Accepted on: January 2015
For Correspondence
Email ID: mauryarp_bh@yaho.com

Abstract: Traumatic subconjunctival dislocation of lens (phacocele or lenticle) is of relatively rare occurrence. We report unusual case of missed subconjunctival dislocation of cataractous lens following blunt ocular trauma by cow horn in an elderly patient without having any previous ocular surgery or trauma. The pathophysiological mechanism, clinical presentation and management are discussed.

Keywords: Blunt ocular trauma, cow horn injury, phacocele, subconjunctival lens dislocation, sclera rupture.

Introduction:

The term phacocele is derived from Greek word "phaco" meaning lens and "kele" meaning hernia. Phacocele (synonym = lenticle) is defined as the anterior dislocation/hernia of crystalline lens into the subconjunctival space through sclera rupture. Phacocele is a rare event caused by severe indirect blunt trauma. It has been reported that phacocele occurs in less than 13 % of all lens dislocation [1]. It was first reported by Friejer in 1928 [2]. Several predisposing factors which favor sclera rupture with lens dislocation are previous large surgical scar of cataract extraction /trebeculectomy/old trauma, diseases of eye wall like scleritis and connective tissue disorder and long term topical medications [3] etc. We reported here an interesting case

of dislocation of cataractous lens caused by indirect trauma by cow horn, without any predisposing factors.

Case report:

A 60 year old male, milkman sustained blunt trauma to his left eye by the cow horn one week prior to presentation. He noticed sudden loss of vision, pain and redness in his left eye following the trauma, for which he was treated non surgically by local general practitioner and did not improve. There was no history of any previous ocular surgery, trauma, recurrent attack of pain and redness in eye and long term topical medications. No other significant personal or family history was found.

On eye examination his visual acuity in left eye was light perception which was not improved with stenopic spectacles and

best corrected visual acuity of the right eye was 6/18. Intraocular pressure (IOP) was 18mmHg in the right eye and 22mmHg in the left eye. Extraocular movement was normal in both eyes. By lifting upper eyelid, left eye showed well delineated subconjunctival mass in superonasal bulbar conjunctiva close to the limbus with small subconjunctival haemorrhage near superotemporal limbus, was the likely site of scleral rupture. There was shallow anterior chamber, pupil was jet black and irregular & peaked in the superotemporal direction. [Figure-1]. Slitlamp examination revealed aphakia. Direct ophthalmoscopic examination did not reveal any fundus detail due to vitreous haemorrhage. B-scan ultrasonography of left eye revealed absence of lens from normal anatomical position with vitreous haemorrhage. There was 3.13mm echogenic shadow in subconjunctival region on the nasal side. Computerized tomography also showed prolapsed lens in subconjunctival space [Figure- 2 & 3]. Right eye examination was within normal limit, except early cataractous changes.

The patient was admitted and was operated for removal of the dislocated lens and closure of scleral defect. The possible need for future vitrectomy and secondary scleral fixated IOL. The conjunctival exploration was done under local anaesthesia by superonasal peritomy and dislocated subconjunctival cataractous lens was removed [figure- 4] and sclera defect of superotemporal perilimbal area was repaired by 10-0 nylon suture. Postoperative recovery was normal without any complication.

Discussion:

Phacocele is a rare phenomena mainly caused by blunt trauma of sufficient magnitude leading to indirect sclera rupture of the globe.[4]. Predisposing factor for subconjunctival dislocation of lens following trauma (even in mild intensity) are hard lens as in advanced age or cataractous lens, increased scleral rigidity may occur as a

result of advanced age and or long standing high IOP (Glaucoma) [5] and weakening pathologies in eyeball such as post surgical scar, scleritis, rheumatoid arthritis and other connective tissue disorders [3]. Subconjunctival luxation of crystalline lens occurs exclusively in elderly beyond 40 year of age and is very rare in children, inspite of high incidence of trauma due to elasticity of outer coats of the globe and softer crystalline lens [4].

In our case predisposing factor was sclera rigidity due to advanced age and hard cataractous lens.

Although common site for indirect scleral rupture is the superonasal quadrant [3] followed by superotemporal quadrant [6] but Charan and Mathur [7] reported inferior luxation of lens and Kramar [8] reported superotemporal displacement. In indirect blunt trauma energy projected from site of impact towards superiorly and posteriorly the globe collides with the orbital wall resulting in sclera rupture [3]. Rupture usually occur at 2.5mm, concentric to limbus where tense and deep scleral fibers are transmitted into delicate lamella of pectineous ligament.[9].

Our case has interesting presentation where the subconjunctival dislocation of cataractous lens in superonasal quadrant was caused by cow horn and remained unnoticed for a month.

We concluded that early detection, timely and appropriate intervention can result good recovery of visual function.

References:

1. McDonald PR, Purnell JE. The dislocated lens. JAMA 1951; 145:220-6.
2. Fejer A J, Subconjunctival lens dislocation. Am J Ophthalmol 1928; 11:254-6.
3. Bueso S, Frances S, Valle D, Troyano J et al. Ocular rupture associated with lens dislocation to the subconjunctival space. Arch Soc Esp Oftamol 2007;82:641-644.

4. Bhattacharjee K, Bhattacharjee H, Deka A, Bhattacharjee P. Traumatic Phacocele; Review of eight cases. *Indian Journal of Ophthalmology* 2007; 55:466-8.
5. Ozcan AA, Yagmur M, Yalaz M. Management of scleral defect with phacocele.
6. Cherry PM. Indirect traumatic rupture of the globe. *Arch Ophthalmol* 1978; 96:252-6.
7. Charan H, Mathur GB. Subconjunctival dislocation of lens. A case report. *Int. Surg.* 1969; 52:115-6
8. Kramar PO, Brandt DE. Subconjunctival dislocation of the lens. *Arch Ophthalmol* 1976; 94:110-1.
9. Sony P, Khokhar S, Panda A. Traumatic lenticle. *Clinical experimental ophthalmol* 2005.

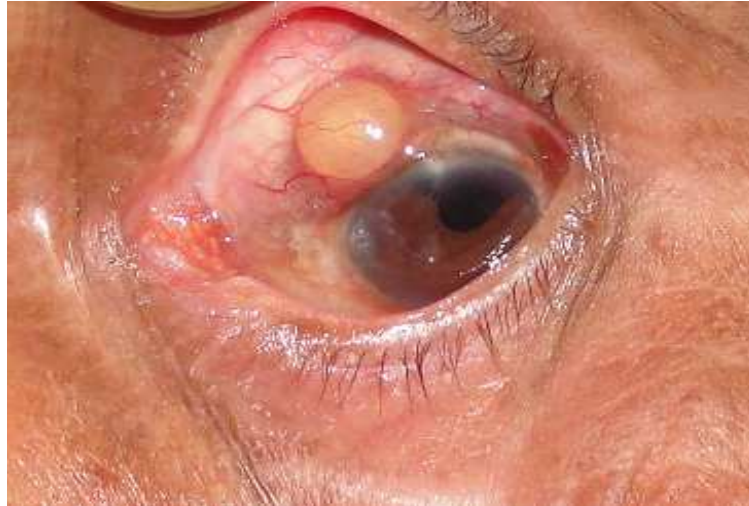

Figure 1: Photograph of the patient showing Subconjunctival dislocation of cataractous lens

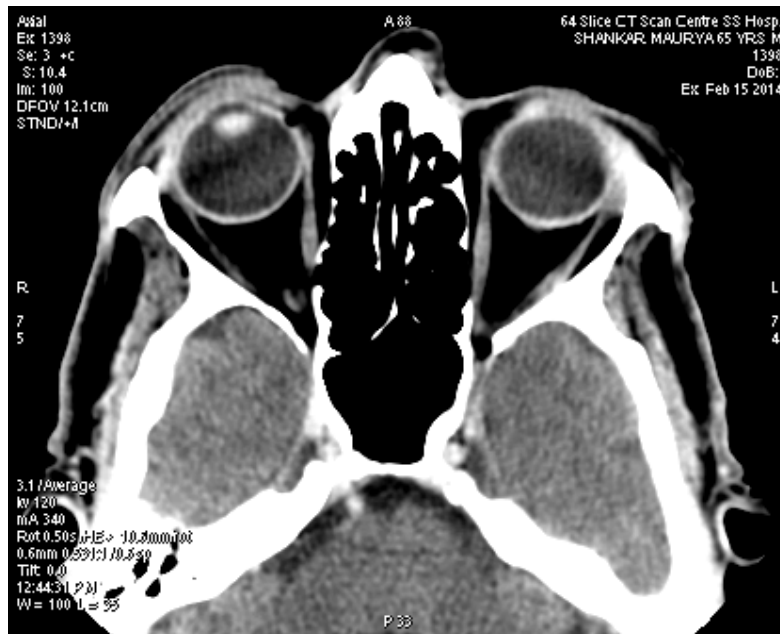


Figure 2: C T scan (axial view) showing left eye Aphakia and dislocated lens

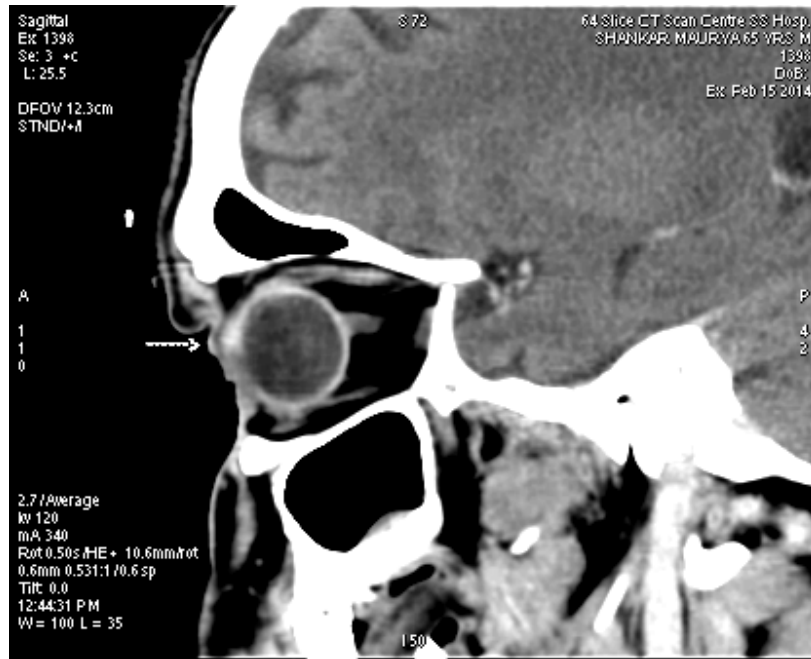


Figure 3: C T (sagittal view) showing sub conjunctival dislocated cataractous lens

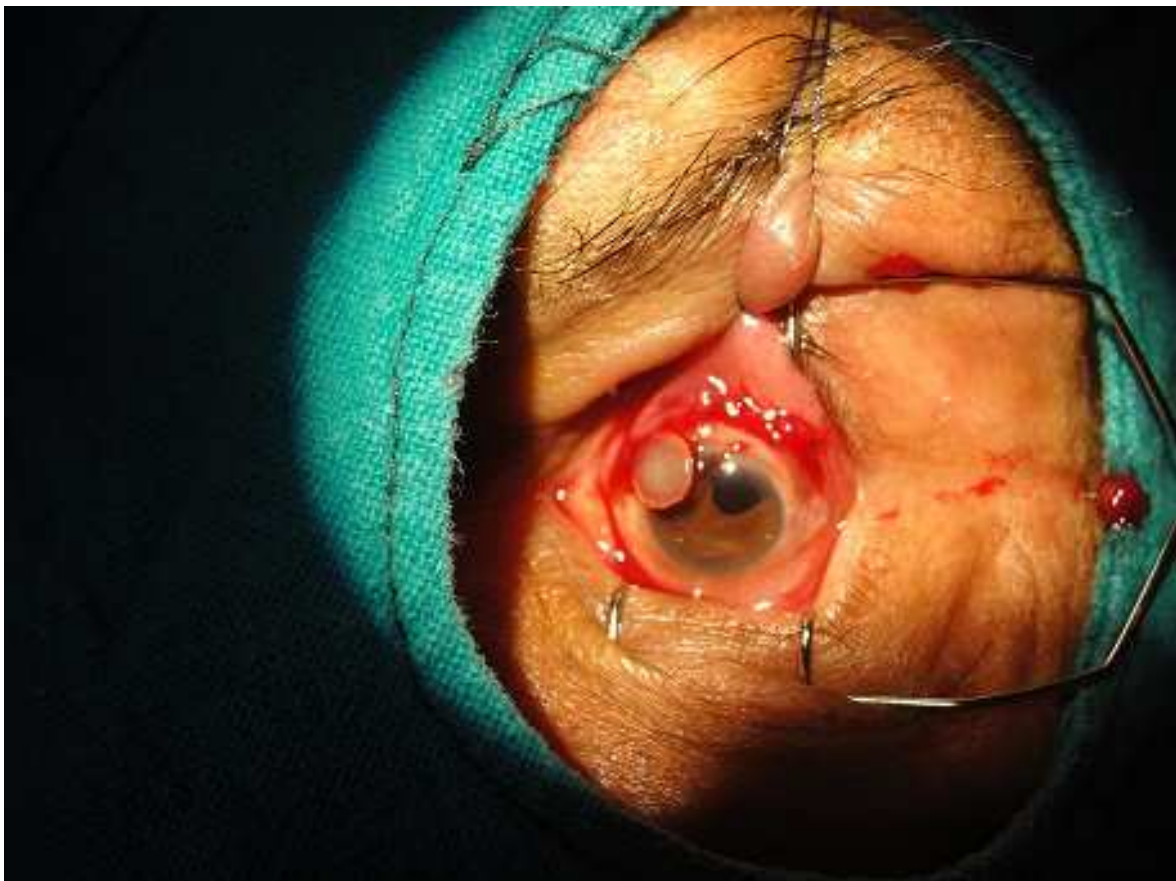

Figure 4: Surgical removal of dislocated lens