



## MEDICO RESEARCH CHRONICLES

ISSN NO. 2394-3971

DOI No. 10.26838/MEDRECH.2022.9.2.592

Contents available at [www.medrech.com](http://www.medrech.com)

### ORAL AND MAXILLOFACIAL MYIASIS: A LITERATURE REVIEW

**Dr. Neha Umakant Chodankar<sup>1</sup>, Dr. Vikas Dhupar<sup>2</sup>, Dr. Francis Akkara<sup>3</sup>, Dr. Rakshit Khandeparker<sup>4</sup>, Dr. Nadia Fernandes<sup>5</sup>**

1. Resident, Department of Oral and Maxillofacial Surgery, Goa Dental College and Hospital, Bambolim Goa- 403202

2. Professor and head, Department of Oral and Maxillofacial Surgery, Goa Dental College and Hospital, Bambolim Goa- 403202

3. Professor, Department of Oral and Maxillofacial Surgery, Goa Dental College and Hospital, Bambolim Goa- 403202

4. Lecturer, Department of Oral and Maxillofacial Surgery, Goa Dental College and Hospital, Bambolim Goa- 403202

5. Junior Resident, Department of Oral and Maxillofacial Surgery, Goa Dental College and Hospital, Bambolim Goa- 403202

#### ARTICLE INFO

##### Article History

Received: March 2022

Accepted: April 2022

##### Key Words:

Oromaxillofacial, Maggots, larvae, necrosis, debridement, ivermectin

##### Corresponding author

**Dr. N. U. Chodankar\***

#### ABSTRACT

The term “Myiasis” refers to the invasion of tissues and organs of animals and humans by the dipteran larvae. The infestation leads to the gross destruction of vital tissues. Oro-maxillofacial myiasis is a rare and unique condition due to the abundance of vascularity in the region and the fact that the oral cavity is least conducive to the growth of larvae and the completion of their lifecycle. The disease is more frequent in under-developed countries with a hot humid climate. It is associated with debilitating medical conditions, poor oral hygiene, malignancy, alcoholism, suppurative lesions, and mainly with unhygienic and poor living conditions. It can be diagnosed solely on clinical examination due to the presence of larvae. This article focuses on etiopathogenesis, clinical features, and treatment modalities of oral and maxillofacial myiasis.

#### REVIEW ARTICLE

2022, [www.medrech.com](http://www.medrech.com)

### INTRODUCTION

The term “Myiasis” first introduced by Hope HW in 1840 can be traced back to its origin from the Latin words “*Muia*,” which means fly and “*iasis*,” which means disease. It was rightly defined by Zumpt as ‘the infestation of live humans and mammals with

dipterous larvae which, at least for a certain period, feed on the host’s dead or living tissues, liquids, body substances or ingested food and develop as parasites.’(1). It has also been defined as “any disease that results from the infestation of tissues or body cavities by larvae of flies”(2).

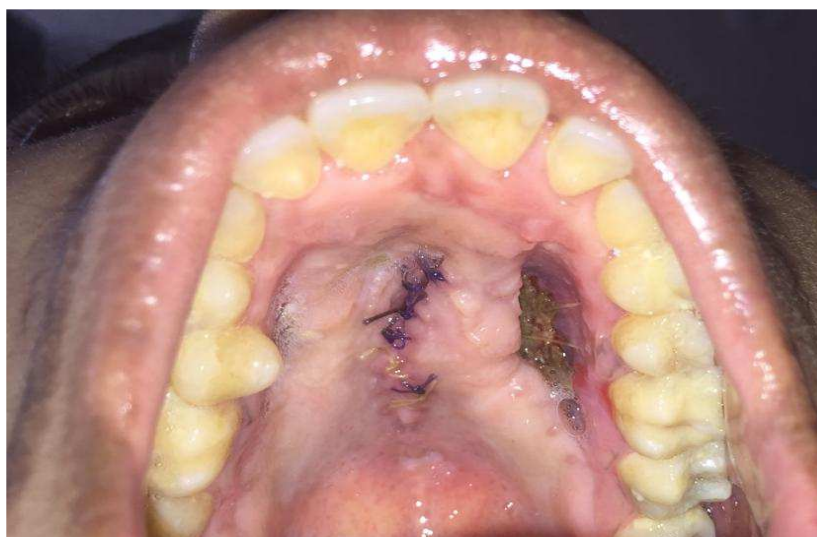Gutierrez, in 1990 described Myiasis as a skin infestation caused by developing larvae of a fly species belonging to the Diptera family. Eggs or larvae laid on food may produce an infection on its ingestion (accidental myiasis), laid directly on wound necrotic tissue (semispecific myiasis) or in some species requiring living tissue, laid directly on to undamaged skin (obligatory myiasis)(3,4). Shira in 1943 reported the first case of oral myiasis(5). Oral myiasis is an uncommon disease in humans and can manifest as an infection of the skin, gut, nasal cavities, eyes, and occasionally the oral cavity. Fly larvae can destroy vital tissues, inducing serious or even life-threatening haemorrhages, so the early diagnosis and management of such infections is essential.(6)

The Diptera fly species have a worldwide distribution bare is seen in high prevalence in tropical and subtropical countries(7). The infestation has a seasonal variation associated with the tropics and the life cycle of the species. Human and animal tissue serves as an intermediate host in the life cycle of these organisms. (8).

#### **EPIDEMIOLOGY AND SITE OF OCCURRENCE**

Myiasis is known to occur predominantly in countries with hot humid weather(9). The countries most affected by this disease are India, Tunisia, Brazil, and Australia. The social nature of the disease can be demonstrated by its higher incidence in underdeveloped or developing countries like India, Tunisia, and Brazil (10). It is extremely rare in Europe and northern hemisphere countries(11). It is also known as “traveller’s disease” since it is mostly seen in travellers from tropics and subtropics(12,13). A slight male predilection has been observed in literature. It has been seen to occur at any age, and may occur in both children and older adults(12).

Oral myiasis is most commonly seen affecting the anterior part of the oral cavity including both jaws and the palate suggesting direct inoculation of tissues(14). The palate is the most commonly involved site. The incidence of extraoral myiasis is higher than that of oral myiasis. This can be attributed to the fact that the tissues of the oral cavity are not always exposed to the external environment(10,15). The gingiva is a rare location for the disease (16).



**Figure no 1:** Clinical photograph of a case of Palatal Myiasis

**CLASSIFICATION**

Myiasis has been chiefly categorized into: anatomical and ecological classifications. The anatomical classification put forth by Bishopp, classifies the infestation about the location on the host and it aids in clinical diagnosis(17–19). The same location may be

infested by different species hence, a classification system based on the degree of parasitism of the fly is also enumerated.

**Anatomical Classification**

The anatomical classification system proposed by Bishopp was later modified by James and by Zumpt (8,17,19).

**Table no 1:** Anatomical Classification of Myiasis

Classification by Bishopp	Classification by James	Classification by Zumpt
Bloodsucking	Bloodsucking	Sanguinivorous
Tissue-destroying	Furuncular	Dermal/subdermal
Subdermal migratory	Creeping	
	Traumatic/wound	
	Anal/vaginal	
Infestation of the head passages	Nose, mouth, sinuses	Nasopharyngeal
	Aural	
	Ocular	

A comprehensive classification combining all three classifications is commonly used to avoid confusion(8):

- Sanguinivorous or bloodsucking
- Cutaneous myiasis, furuncular and migratory
- Wound myiasis

- Cavitory myiasis, e.g., cerebral myiasis, aural myiasis, nasal myiasis, and ophthalmomyiasis.

**Ecological Classification**

Ecological classification is based on the level of parasitism of the parasite and the host(8).

**Table no 2:** Ecological Classification of Myiasis

Ecological classification	Description
Specific/obligatory	Parasites dependent on their host for part of its life cycle
Semispecific/facultative	
Primary	Free-living and may initiate myiasis
Secondary	Free living and unable to initiate myiasis; may be involved once animal is infested by other species
Tertiary	Free living and unable to initiate myiasis; may be involved when the host is near death
Accidental/pseudomyiasis	Free-living larva and not able to complete its life cycle; causes a pathological reaction when accidentally in contact with the host

## Etiology

### Causative Organism

Oral myiasis is a condition in which the soft tissues of the oral cavity are invaded by the parasitic larvae of the flies(5). Although *C. hominivorax* larvae are the main agent of myiasis(10), it can be caused by several species, of which the Calliphoridae, Sarcophagidae and Oestridae families are considered as the main causative families. (20) Other species, such as *Cordylobia anthropophaga*, *Wohlfahrtia magnifica*, *Chrysomya bezziana*, *Hypoderma bovis*, *Hypoderma tarandi*, *Musca nebulosa*, *Musca domestica*, and *Lucilia sericata* have also been reported as causes of this infestation (10,11,21,22).

### Etiopathogenesis

The life cycle of these organisms is made up of four stages: (12,23–28)

**Egg stage:** After the fly lays eggs in the dead and decaying tissues, the larvae hatch in about 8-10 hours.

**Larva stage:** This stage includes three sub stages namely, first, second and third instar stage known as maggots during which it is 11 to 15 mm in diameter. The larvae are short stout, greyish white in colour with a dark tip posteriorly and have a tapered shape with transverse rows. After the third instar stage, the maggot undergoes pupation by burrowing into the surrounding tissues to form

a tract and may even cause separation of the mucoperiosteum from the bone. This stage marks the onset of tissue inflammation and discomfort. The opening of this burrow allows respiration.

Induration of the surrounding tissues is noted which forms a dome-shaped swelling known as “warbles”. The larvae stage lasts for 6-8 days during which they are parasitic on human beings and anchor themselves to surrounding tissues to form a niche for further development. The toxins released by the larvae in conjunction with enzymes released by the surrounding bacteria decompose the host tissue. The larvae feed on this necrotic tissue which frequently releases a foul-smelling discharge. The toxin and enzyme interaction causes bony necrosis and erosions(29).

**Pupal stage:** In about 12 days they develop into the pre-pupal stage and leave the host by wriggling out of the wound and onto the ground to pupate and emerge as adult flies after 5-15 days.

**Adult fly stage:** The adult female flies lay over 500 eggs directly over the diseased tissue, the eggs hatch in less than a week and the life cycle reaches completion in about 2 weeks. The conditions suitable for the egg laying and the survival of the larvae are the moisture, necrotic tissue and optimal temperature(7).

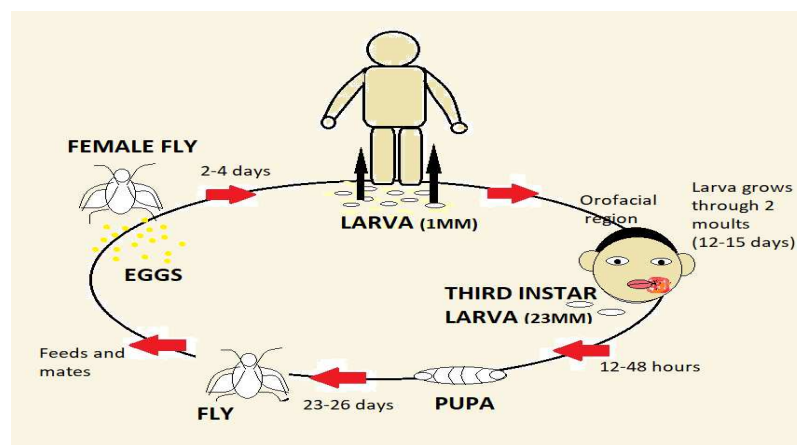


Figure no 2: Life cycle of Flies

A myiasis infection can be a very serious condition. *C. Hominivorax* is known to deposit up to 400 eggs on open wounds. Necrobiophagous flies feed on necrotic tissue and produce secondary myiasis. It affects patients with lesions in necrotic cavities(2).

### Predisposing factors

Literature suggests that, myiasis is most commonly seen in patients who need assistance and are not able to take care of themselves. The predisposing factors constitute the following:

Lifestyle factors(12,20,23,30,31):

- Living in proximity to livestock and domesticated animals
- Rural areas
- Alcoholism
- Unhygienic and poor living conditions

Medical conditions (12,20,23)

- Diabetes Mellitus
- Psychiatric illnesses like disorders that affect mood, thinking and behaviour
- CNS disorders namely cerebral palsy, hemiplegia, neurological defect, learning disability, epilepsy etc

- 

- Leprosy
- Senility
- Nosocomial diseases
- Peripheral vascular disease(32)

Local risk factors(11,13,20,23,31):

- Lack of manual dexterity
- Poor oral hygiene
- Ill-fitting dentures
- Uncleaned prosthesis
- Advanced periodontal disease
- Tooth extraction sites
- Thumb-sucking habits
- Incompetent lips
- Mouth breathing
- Patients undergoing mechanical ventilation
- Halitosis
- Facial trauma
- Anterior open bite

Pathological conditions(23)

- Cancrum oris
- Malignancy
- Suppurative lesions

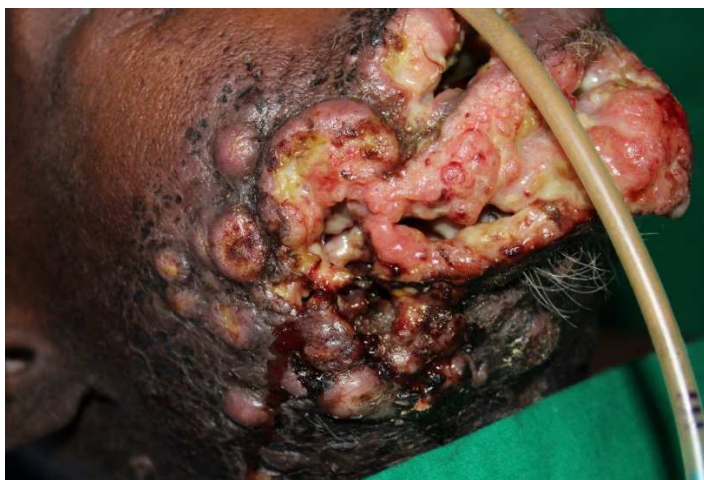

Figure no 3: Clinical photograph of a case of Myiasis in Oral Carcinoma

### Clinical Presentation



The clinical manifestations of myiasis infestation include(23,32,33)

- Painful erythematous swellings with itching
- Ulcers
- Crawling sensation
- Maggots coming out of wounds
- Furuncular or boil like lesions called “Berne”
- It could be benign, asymptomatic or with mild or acute pain
- Sloughing necrotic tissue
- Foul smell and halitosis
- Fungating repulsive appearance
- Mild bleeding or blood-stained discharge
- Exposed nonvital bone
- Loose teeth
- May have a cellulitic response associated with secondary bacterial infection by *Staphylococcus aureus*(34).
- May also present with abscess formation, osteomyelitis and tetanus(35).

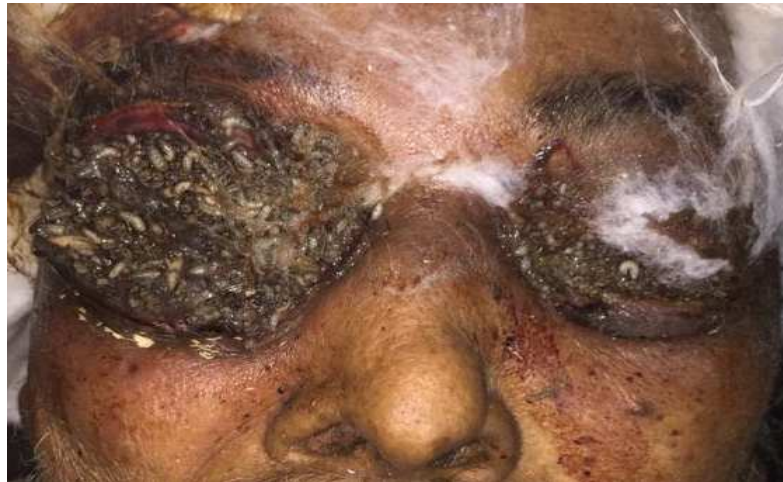

Figure no 4: Clinical photograph of a case of Myiasis of both Orbits

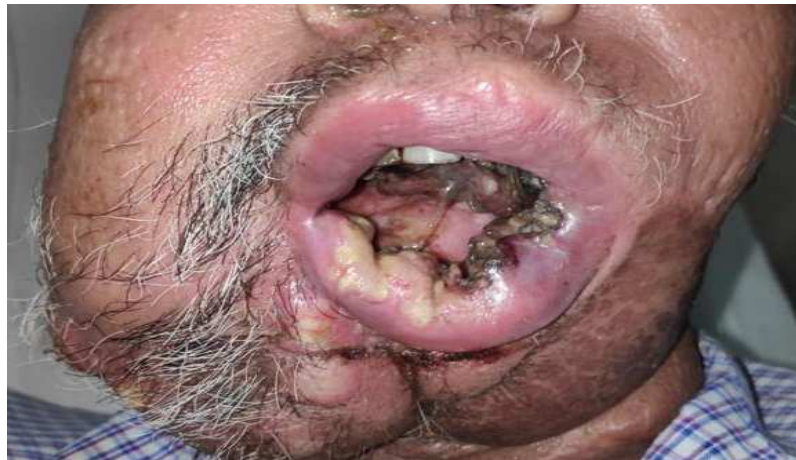

Figure no 5: Clinical photograph of a case of Myiasis in Operated Oral Carcinoma

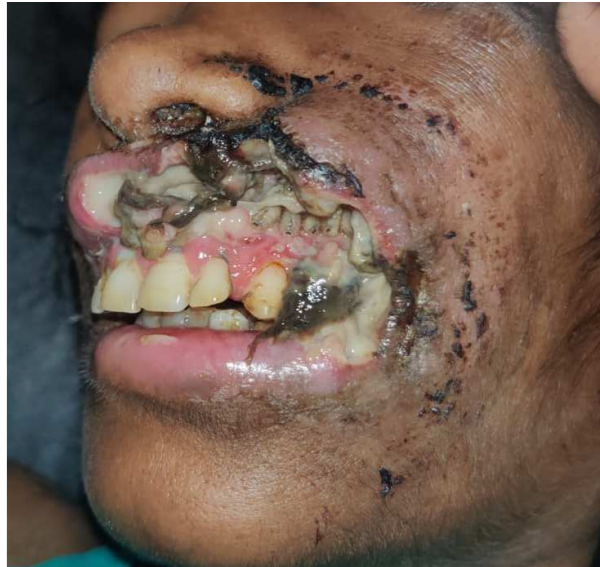

Figure no 6: Clinical photograph of a case of Myiasis of Lips and Upper Alveolus

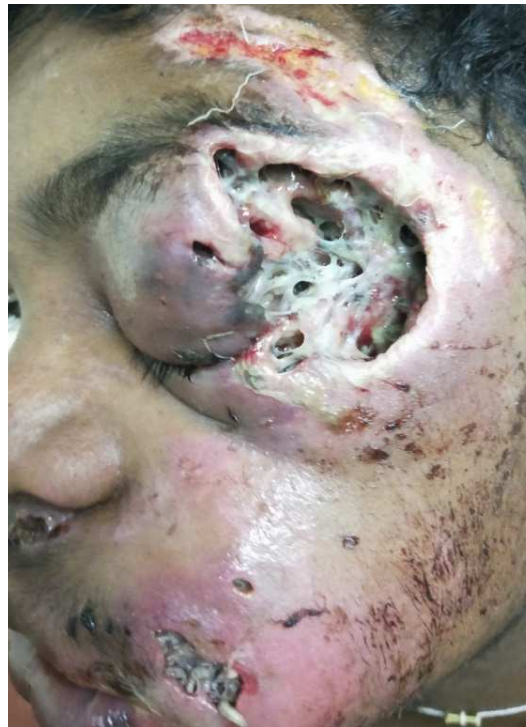

Figure no 7: Clinical photograph of a case of Myiasis of Multiple Orofacial regions

### **Radiographic Findings**

Radiography is crucial in widespread cases in order to rule out the involvement of vital structures like the orbit and brain or even to check for spread into the deeper pharyngeal spaces.

Conventional radiographs may show radiolucency suggestive of bone resorption (36)

Computed tomography scans or magnetic resonance imaging may be done. The findings to be noted are(37):

- Mucoperiosteal thickening and an air-fluid level in maxillary sinus
- Intra oral, extraoral, intranasal and nasopharyngeal edema and congestion
- Scattered areas of ill-defined rounded hypolucencies within the edematous soft tissues
- Edema of periorbital soft tissues without frank abscess
- Opacification of ethmoid sinuses
- Congestion of turbinates
- Erosion and perforation of surrounding bone and even the cartilaginous nasal septum
- Other findings to be noted are involvement of orbital contents that will be seen as perforation of orbital bones and edema and distortion of the eyeball and its surrounding tissues in extensive cases(38).

### **Management**

The standard guidelines for treatment of myiasis focus on antibiotic therapy in conjunction with mechanical removal of necrotic tissues(9,39). There is no standard protocol for the management of oromaxillofacial myiasis(7).

### **Surgical management**

The treatment of choice is the removal of all the larvae and surgical debridement of the site with or without the use of systemic medication according to the severity of the infestation and the general condition of the patient. Debridement serves a curative

function, however foreign- body reactions may occur, leading to incomplete debridement and persistence of larvae in the surgical wound. (9,11,40) The need for immediate treatment has been stressed in literature to avoid potential complications, like extensive tissue destruction, palatal perforation, and cavernous sinus thrombosis(10,41,42).

### **Adjuvant Treatment**

Adjuvants to treatment include drugs like ivermectin and antibiotics to combat the co-existing bacterial infection(43). Ivermectin is a semi-synthetic macrolide antibiotic, derived from avermectins and has anthelmintic properties. It is a broad spectrum, fast acting, anti-parasitic agent (12) that blocks the nerve impulses in the nerve endings of parasites causing their paralysis and death(41,44). The dosage of Ivermectin is generally, 150 to 200 mg/kg body weight, administered in a single dose. It undergoes rapid absorption and attains high blood concentrations in a short time span. This induces the larvae to be quickly expelled from the wound.(10,45)

### **Local Agents**

The use of various local agents has been suggested in literature which include turpentine, mineral oil, ether, chloroform, ethyl chloride, mercuric chloride, creosote, saline, phenol, calomel, olive oil, and iodoform, but they have had controversial results(46). The most commonly used and readily available agent is turpentine oil. It is used by either flushing the wound or packing the wound with pallets soaked in turpentine oil. It irritates and asphyxiates the maggots thus, forcing them out of the wound(46,47).

Nitrofurazone is an alternative therapeutic option administered topically. It is a broad-spectrum anti-infective agent that should be administered topically at 0.2% (20ml) concentration over three consecutive days (8,8,9,48). It is placed in direct contact with the wound and the larvae within it. It is



an offensive substance that induces the removal of larvae.

Other chemical agents described in the literature that induces the larvae to leave the wound by causing tissue hypoxia or by the mechanical action of irrigation include, saline, hydrogen peroxide, chlorhexidine, and gentian violet. (10,44,49)

### **Occluding Agents**

Treatment approaches other than the administration of larvicides include, occlusion of the wound. These techniques can be used along with manual removal, or if manual removal is not possible. Occlusion of an infested wound deprives the larvae of oxygen and will either kill them or cause them to move more superficially hence allowing their removal easily. Occlusion of infected wounds can be performed with a variety of substances which include, petroleum, nail polish, animal fat, beeswax, paraffin, hair gel, and mineral oil(7,40).

### **Prevention**

Myiasis can be prevented by rigorous control of fly populations, maintaining oral as well as general hygiene by reducing foul odors and carrying out meticulous cleaning and dressing of wounds. Most essential step to prevent infestation is the control of flies. This can be done by good sanitation practices and fly management programs in the form of elimination of breeding areas and killing of adult flies. Satisfactory levels of sanitation can only be achieved with the collaboration of the government, population and awareness programs. Screens and mosquito nets can be used to prevent flies from reaching the skin. Insect repellents containing Diethyltoluamide can also be used(8,12) Ultraviolet fly traps may be placed every 30 feet along the wall inside a building. Recommended areas for outdoor placement include building entrances, alleyways, beneath trees, around animal sleeping areas and manure piles. Residual wall sprays can be applied in fly swarming areas. Other methods to control fly population

include the use of automatic misters, adding boric acid to outdoor garbage bins, and the use of flypaper, electrocuting traps, and baited traps indoors(6,15,22,50).

### **Sequelae**

The sequelae reported in the literature include loss of vision, hearing loss, salivary gland involvement, development of oro-antral and/or oro-nasal fistulae, extensive bone and soft tissue loss and even death. Early diagnosis and immediate treatment are therefore crucial for interrupting of progression of the disease and preventing disastrous consequences (10,40).

### **CONCLUSION**

Oro-maxillofacial myiasis is an uncommon, preventable disease. Thorough knowledge of its etiopathogenesis and management is essential. Early diagnosis with an appropriate and meticulous surgical exploration of the lesion combined with adjuvant and local measures can prevent considerable tissue damage, and morbidity and can also avert unaesthetic outcomes. Prevention is the best form of treatment.

### **REFERENCES**

1. Novelli MR, Haddock A, Eveson JW. Orofacial myiasis. Br J Oral Maxillofac Surg. 1993 Feb 1;31(1):36–7.
2. Sharma J, Mamatha GP, Acharya R. Primary oral myiasis: a case report. Med Oral Patol Oral Cirurgia Bucal. 2008 Nov 1;13(11):E714-716.
3. Gutierrez Y. Diagnostic Pathology of Parasitic Infections with Clinical Correlations. Oxford University Press; 2000. 810 p.
4. Meinking TL, Burkhart CN, Burkhart CG. Changing paradigms in parasitic infections: common dermatological helminthic infections and cutaneous myiasis. Clin Dermatol. 2003 Sep-Oct;21(5):407-16.
5. Prabhu, S. R. (1992). *Oral diseases in the tropics*. Oxford: Oxford University Press. Available from:

- <https://www.bookdepository.com/Oral-Diseases-Tropics-S-R-Prabhu/9789386150554>
6. Singla V. Oral Myiasis—A Case Report. *J Oral Maxillofac Surg.* 2013 Sep 1; 71(9): 1555.e1-1555.e4.
  7. Bholra N, Jadhav A, Borle R, Adwani N, Khemka G, Jadhav P. Primary oral myiasis: a case report. *Case Rep Dent.* 2012; 2012:734234.
  8. Francesconi F, Lupi O. Myiasis. *Clin Microbiol Rev.* 2012 Jan;25(1):79–105.
  9. Antunes AA, Santos T de S, Avelar RL, Martins Neto EC, Macedo Neres B, Laureano Filho JR. Oral and maxillofacial myiasis: a case series and literature review. *Oral Surg Oral Med Oral Pathol Oral Radiol Endod.* 2011 Dec;112(6): e81-85.
  10. de Arruda JAA, de Oliveira Silva LV, Silva PUJ, de Figueiredo EL, Callou G, Mesquita RA, et al. Head and neck myiasis: a case series and review of the literature. *Oral Surg Oral Med Oral Pathol Oral Radiol.* 2017 Nov;124(5): e249–56.
  11. Droma EB, Wilamowski A, Schnur H, Yarom N, Scheuer E, Schwartz E. Oral myiasis: a case report and literature review. *Oral Surg Oral Med Oral Pathol Oral Radiol Endod.* 2007 Jan;103(1):92–6.
  12. Kumar PS, Ramadas R, Shankaran P, Thampan N. Oral Myiasis: The Diagnostic Conundrum- A Systematic Review. *J Clin Diagn Res* 2019 Sep, Vol-13(9): ZE01-ZE04
  13. N Sharma, D Malhotra, Manjunatha BS and J Kaur Oral Myiasis-A Case Report *Austin J Clin Case Rep.* 2014;1(8): 1039.
  14. Souza ND, Kamat S, Chalakkal P, Da Costa GC. A Rare Occurrence of Oral Myiasis in the Posterior Region of the Jaw. *Int J Contemp Med Res IJCMR* 2018;5(8):H6-H8.
  15. Kumar P, Singh V. Oral myiasis: case report and review of literature. *Oral Maxillofac Surg.* 2014 Mar;18(1):25–9.
  16. Gursel M, Aldemir OS, Ozgur Z, Ataoglu T. A rare case of gingival myiasis caused by diptera (Calliphoridae). *J Clin Periodontol.* 2002 Aug;29(8):777–80.
  17. James MT: *The Flies that cause Myiasis in Man.* Washington, D.C.; 1947. Available from: <https://www.cabi.org/ISC/abstract/19501000278>
  18. Patton WS: *Notes on the myiasis-producing Diptera of Man and Animals.* *Bull. Entomol. Res.* 1921. volume 12, issue 3, P239-261
  19. Fritz Zumpt: *Myiasis in man and animals in the old world; a textbook for physicians, veterinarians and zoologists.* (Book, 1965) [WorldCat.org]. Available from: <https://www.worldcat.org/title/myiasis-in-man-and-animals-in-the-old-world-a-textbook-for-physicians-veterinarians-and-zoologists/oclc/636047>
  20. Srivastava R, Devi P, Thimmarasa VB, Jayadev S. Flies blown disease - Oral myiasis. *Indian J Dent Res.* 2011 Jul 1;22(4):615.
  21. Sankari LS, Ramakrishnan K. Oral myiasis caused by *Chrysomya bezziana*. *J Oral Maxillofac Pathol.* 2010 Jan 1;14(1):16.
  22. Hassona Y, Scully C, Aguida M, de Almeida OP. Flies and the mouth. *J Invest Clin Dent.* 2014 May;5(2):98–103.
  23. Gupta R, Pandey R, Bhagat N, Goyal P. Oral Myiasis: A Short Overview. *Int J Adv Res.* 2016 Apr 19; 4:1064–8.
  24. Pereira T, Tamgadge AP, Chande MS, Bhalerao S, Tamgadge S. Oral myiasis. *Contemp Clin Dent.* 2010 Oct 1;1(4):275.

25. Gabriel JG, Marinho SA, Verli FD, Krause RG, Yurgel LS, Cherubini K. Extensive myiasis infestation over a squamous cell carcinoma in the face. Case report. *Med Oral Patol Oral Cirurgia Bucal*. 2008 Jan 1;13(1): E9-11.
26. Rohela M, Jamaiah I, Amir L, Nissapatorn V. A case of auricular myiasis in Malaysia. *Southeast Asian J Trop Med Public Health*. 2006;37 Suppl 3:91-4.
27. Abdo EN, Sette-Dias AC, Comunian CR, Dutra CEA, Aguiar EG de. Oral myiasis: a case report. *Med Oral Patol Oral Cirurgia Bucal*. 2006 Mar 1;11(2): E130-131.
28. Nasal Myiasis: Case Report and Literature Review [Internet]. [cited 2022 Apr 10]. Available from: [http://www.arquivosdeorl.org.br/conteudo/acervo\\_eng.asp?id=409](http://www.arquivosdeorl.org.br/conteudo/acervo_eng.asp?id=409)
29. Rossi-Schneider T, Cherubini K, Yurgel LS, Salum F, Figueiredo MA. Oral myiasis: a case report. *J Oral Sci*. 2007 Mar;49(1):85-8.
30. Hakimi R., Yazdi I. Oral Mucosa Myiasis Caused by *Oestrus Ovis*. *Archives of Iranian Medicine*. 2002;5(3):194-196.
31. Lukin LG. Human cutaneous myiasis in Brisbane: a prospective study. *Med J Aust*. 1989 Mar 6;150(5):237-40.
32. Sheikh S, Pallagatti S, Singla I, Kalucha A, Aggarwal A, Kaur H. Oral Myiasis-A review. *J Clin Exp Dent*. 2011; e465-8.
33. Rana R, Singh A, Pandurangan S, Gupta P, Udenia H, Agrawal A. Cryptic Myiasis by *Chrysomya bezziana*: A Case Report and Literature Review. *Turk J Ophthalmol*. 2020 Dec 29;50(6):381-386.
34. Messahel A, Sen P, Wilson A, Patel M. An unusual case of myiasis. *J Infect Public Health*. 2010;3(1):43-5.
35. Hakeem MJML, Bhattacharyya DN. Exotic human myiasis. *Travel Med Infect Dis*. 2009 Jul;7(4):198-202.
36. Aggarwal A, Daniel MJ, Shetty RS, Kumar BN, Sumalatha CH, Srikanth E, et al. Oral Myiasis Caused by *Chrysomya bezziana* in Anterior Maxilla. *Case Rep Dent*. 2014 Apr 29;2014: e518427.
37. Duque CS, Mosquera CA, Casiano RR, Abreu CE. Radiologic findings in sinonasal myiasis. *Otolaryngol--Head Neck Surg Off J Am Acad Otolaryngol-Head Neck Surg*. 2006 Oct;135(4):638-9.
38. Huang Y-L, Liu L, Liang H, He J, Chen J, Liang Q-W, et al. Orbital myiasis: A case report and literature review. *Medicine (Baltimore)*. 2020 Jan;99(4): e18879.
39. Villwock JA, Harris TM. Head and neck myiasis, cutaneous malignancy, and infection: a case series and review of the literature. *J Emerg Med*. 2014 Aug;47(2): e37-41.
40. McGraw TA, Turiansky GW. Cutaneous myiasis. *J Am Acad Dermatol*. 2008 Jun;58(6):907-26; quiz 927-9.
41. Shinohara EH, Martini MZ, de Oliveira Neto HG, Takahashi A. Oral myiasis treated with ivermectin: case report. *Braz Dent J*. 2004;15(1):79-81.
42. Alves CAF, Ribeiro O, Borba AM, Ribeiro ANC, Guimaraes J. Cavernous sinus thrombosis in a patient with facial myiasis. *Quintessence Int Berl Ger* 1985. 2010 Apr;41(4):e72-74.
43. Pessoa L, Galvão V. Myiasis infestation in advanced oral squamous cell carcinoma. *BMJ Case Rep*. 2011 Jul 15;2011: bcr0420114124.
44. Silva WPP da, Barbosa S, Coelho Mendes B, Diego Pavelski M, Santos AM de S, Silva MC, Santos JMF e, Magro Filho O, Faverani LP. Clinical and systemic management of myiasis in

- a patient with advanced Alzheimer's disease. RSD. 2021Mar.8 ;10(3):e12110313145.
45. Gealh WC, Ferreira GM, Farah GJ, Teodoro U, Camarini ET. Treatment of oral myiasis caused by *Cochliomyia hominivorax*: two cases treated with ivermectin. *Br J Oral Maxillofac Surg*. 2009 Jan;47(1):23–6.
46. Patel BC, Ostwal S, Sanghavi PR, Joshi G, Singh R. Management of Malignant Wound Myiasis with Ivermectin, Albendazole, and Clindamycin (Triple Therapy) in Advanced Head-and-Neck Cancer Patients: A Prospective Observational Study. *Indian J Palliat Care*. 2018;24(4):459–64.
47. Kumar SL, Manuel S, John TV, Sivan MP. Extensive gingival myiasis - Diagnosis, treatment, and prevention. *J Oral Maxillofac Pathol JOMFP*. 2011 Sep;15(3):340–3.
48. Lima LB, de Miranda RBM, Furtado LM, Rocha FS, Parreira da Silva MC, Silva CJ. Reconstruction of orbital floor for treatment of a pure blowout fracture. *Rev Port Estomatol Med Dentária E Cir Maxilofac*. 2015 Apr 1;56(2):122–6.
49. Filho AO, Dias D, Miranda Á, Hebling E. Oral myiasis in the older adult with severe Alzheimer's disease. *Spec Care Dent Off Publ Am Assoc Hosp Dent Acad Dent Handicap Am Soc Geriatr Dent*. 2018 Mar;38(2):99–106.
50. Featured Creatures [Internet]. Available from: <https://entnemdept.ufl.edu/creatures/>
-