

TRICHOFOLLICULOMA OF EXTERNAL AUDITORY MEATUS: A CASE REPORT

Shivakumar S.¹, Paul V. J.², Shankar R.³

1. Professor, Department of Otorhinolaryngology & Head and Neck Surgery, V.M.K.V.M.C.H, Salem.
2. Post-Graduate, Department of Otorhinolaryngology & Head and Neck Surgery, V.M.K.V.M.C.H, Salem.
3. Associate Professor, Department of Community Medicine, VMKVMCH, Salem

Submitted on: March 2015
Accepted on: March 2015
For Correspondence
Email ID:
shnkr_radhakrishnan@yahoo.com

Abstract:

Trichofolliculoma is a benign hair follicle hamartoma. It represents differentiation of pluripotent skin cells towards hair follicles. Usually seen in the Head and Neck region; the face and scalp are the common sites. Presentation in the External Auditory Meatus is very rare.

We present here a case of 19 year old female presenting with a swelling in External Auditory Meatus which turned out to be Trichofolliculoma. The case was treated with Surgical Excision. Patient has been followed up post-op. for the past 3 months with no recurrence.

Introduction:

Trichofolliculoma is a rare benign lesion of the hair follicle; a hamartoma. (1) Commonly seen in the face and scalp (2), it is rarely seen in nose, penis, uvula and scrotum. Though it is seen in commonly seen in adults, it is also seen in children as congenital lesion (3). There is no sexual preference, but some literature suggests male preference (4). It is commonly asymptomatic presenting because of cosmetic reasons. Trichofolliculoma of the External Auditory Meatus is a rare occurrence and very few cases have been reported as of now.

Case Report:

A 19yrs old female came to the ENT OPD, with complaints of swelling in the Left External Auditory Meatus since 4yrs. Insidious in onset, started as small swelling

gradually progressive in size for 3 ¾ years. The swelling has rapidly increased in size over the past 3 months.

Examination showed swelling in the Left External Auditory Meatus. Further clinical examination revealed an oblong swelling which was around 2.5x1 cm in size.

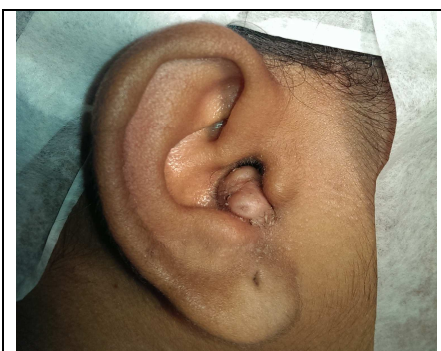


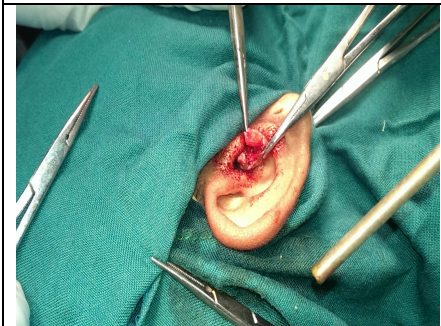


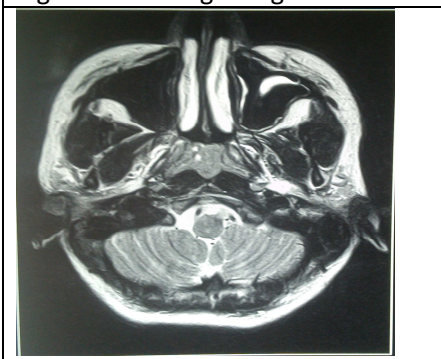
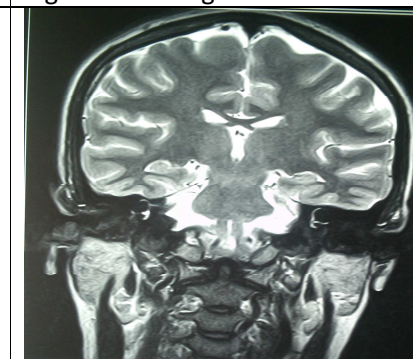
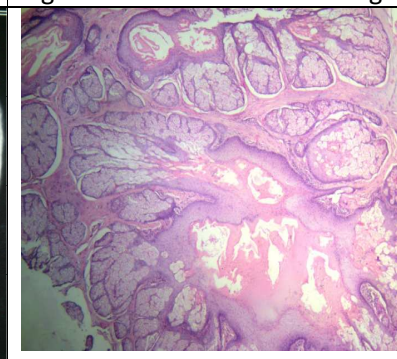
The surface was irregular and the swelling firm in consistency. No cough impulse was elicited and the swelling was not reducible.


MRI Scan revealed a small linear mildly Hyper intense to muscle noted posterior to tragus extending to Right External Auditory meatus measuring 1.3x1 cm. Contrast Enhancement noted. Lesion situated in superficial plane.

The patient was subjected to surgery under general anesthesia and Excision done. The swelling was 1.5x 1cm in size and

oblong in shape. The swelling when cut across was firm and the cut surface showed a worly appearance. The material was then sent for histopathological examination

which confirmed the presence of Triculofolliculoma. Post-Operatively the patient was put on Antibiotics – Cefixime 200mg bd x 7 days.

		
Figure1: Right Ear showing swelling.	Figure2: Incision being applied.	Figure3: Swelling being dissected.
		
Figure4: Swelling being removed.	Figure5:Swelling after removal	Figure 6:Cut section of swelling
		
Figure7: MRI Axial view showing swelling.	Figure8: MRI Coronal view showing swelling.	Figure9: HPE [H&E-10X]

		
<p>Figure10: HPE [H&E-100X]</p>	<p>Figure11: : Wound picture on day 5</p>	

Discussion:

Trichofolliculoma is a uncommon benign Hamartoma of the Pilosebaceous Follicle. The exact etiology is still uncertain but may be because of unsuccessful differentiation towards hair follicles of the pluripotent skin cells(5). The neck, nose, genitalia., lip, and the external auditory meatus represent the rare areas of occurrence. Commonly seen as a flesh colored swelling, it presents as a nodule/ papule less than 0.5 cm in size usually, but it can also present as large lobulated mass(6). The presence of small tuft of white vellums hairs protruding from a central osmium is distinctive of Trichofolliculoma(7).

The diagnosis is based on clinical examination, MRI Scan, FNAC(8). MRI Scan revealed the presence of small enhancing mildly hyper intense lesion with the possibility of fibroma. The diagnosis finally is confirmed only by histopathological examination after surgical excision. Histopathological examination revealed a neoplasm composed of a central hair follicle with numerous Sebaceous glands seen arising from it. Sebaceous glands are arranged in lobules. Germinative cells are minimal.

The swelling may at times present along with focal Acantholytic dyskeratosis(9) or with other adnexal tumours such as Trichogenic Myxoma(10).

In our case there were no other associated presentations. Following complete excision, recurrence is rare ;though there are reports of a recurrent Trichofolliculoma of upper eyelid(11). Malignant transformation can occur as reported in a case with perineural invasion(12).

Conclusion:

We have presented a case of Trichofolliculoma of External auditory meatus; a rare site of occurrence: which was diagnosed and managed by simple excision under General Anesthesia. MRI Scan indicated the possibility of a Fibroma. The final confirmation is by histopathological examination after excision which turned out to be Trichofolliculoma .Patient has been followed up for a period of 3 months with no recurrence. Complete Surgical excision is mandatory keeping in mind the possibility of recurrence and malignant transformation

References:

1. Tricho folliculoma in External Auditory canal. Ju Young Hong; Joong Kim; Sun A Choi; and Seung Geun Yeo, Korean Journal of Otorhinolaryngology – Head & Neck Surgery: Volume 57, No-12, (12/2014) – Case Report 847 – 9.
2. Trichofolliculoma: a rare variant of hair follicle hamartoma, Hilal Gokalp MD, Mehmet Ali Gurer Professor, Saadet Alan MD Dermatology Online Journal 19(8):7

3. Ishii N, Kawaguchi H, Takahashi K, Nakajima H. A case of congenital trichofolliculoma. *J Dermatol.* Mar 1992; 19(3):195-6. (PMID1640026).
4. Umbilicated nodule over eyebrow. Nidhi Singh MD, Nava Kumar MBBS, Laxmisha Chandrashekar MD DNB, Devinder Mohan Thappa MD DHAMNAMS, Rakhee Kar MD, Bheemanathi Hanuman Srinigas MD. *Dermatology Online Journal* 19(9):12
5. Trichofolliculoma presenting as Lobulated Mass:A Rare presentation Jyotsna Naresh Bharti, Biswajit Dey, Parul Gautam, Parth Desai, and VINAY Kamal *International Journal of Trichology.* 2014 Jan-Mar;6(1):19-20
6. Schulz T, Hartschuh W. The Trichofolliculoma undergoes changes corresponding to the regressing normal hair follicle in its cycle. *J Cutan Pathol* 1998;25(7): 341- 53. PMID:9765019 [PUBMED]
7. Trichofolliculoma of Nasal vestibule: A rare case report. Pradip M, Santosh D, Gautamjit RK, Niteshore M, Nicola CL Priyoshakhi H. *IOSR Journal of Dental & Medical Sciences.* e ISSN: 2279-0853, P. ISSN: 2279-0861: Volume 13, Issue – 7, ver IV (July 2014), PP(26-27).
8. Alexander MP, Makhija p, Jayaseelan E. Fine Needle Aspiration Cytology of Trichofolliculoma: a case report. *Indian Journal of Pathology & Microbiology* 2007; 50:870-2.
9. Bogle MA, Cohen PR, Tschen JA. Trichofolliculoma with incidental focal acantholytic dyskeratosis. *Med J.* Aug 2004; 97(8) :773-5.7.
10. Cohen C, Davis TS. Multiple trichogenic adnexal tumours. *Am J Dermatopathol* 1986;8(3) : 241-6.
11. Recurrent Trichofolliculoma of upper eyelid margin morton AD, Nelson CC, Headington JT Einer VM. *Ophthalmology plastic reconstructive surgery* 1997, Dec;13(4) : 287-8.
12. Stern JB, Stout DA. Trichofolliculoma showing perineural invasion. Trichofolliculocarcinoma? *Arch Dermatol* 1979;115(8):1003-4 PMID: 464613 (Pubmed)